

Case Reports

Increasing Evidence for the Use of Sodium Oxybate in Multi-Drug-Resistant Lance–Adams Syndrome

Giulietta M. Riboldi* & Steven J. Frucht

The Marlene and Paolo Fresco Institute for Parkinson's and Movement Disorders, Department of Neurology, New York University School of Medicine, New York, NY, USA

Abstract

Background: Treatment of posthypoxic myoclonus (PHM) can be a challenge in patients not responsive to first-line medications. PHM is a rare condition that has a dramatic impact on patients' quality of life. Refractory cases are not uncommon.

Case report: We report a patient with PHM non-responsive to conventional treatments who showed a dramatic improvement with sodium oxybate (SBX). Cases of PHM treated with SBX reported in the literature were reviewed.

Discussion: Resting and stimulus-induced myoclonus respond robustly to SBX, with significant improvement in patients' quality of life. SBX may be considered in patients with PHM resistant to first-line medications.

Keywords: Posthypoxic myoclonus, Lance–Adams syndrome, refractory myoclonus, alcohol-sensitive myoclonus, sodium oxybate

Citation: Riboldi GM, Frucht SJ. Increasing Evidence for the Use of Sodium Oxybate in Multi-Drug-Resistant Lance–Adams Syndrome. Tremor Other Hyperkinet Mov. 2019; 9. doi: 10.7916/d8-rnsh-c024

*To whom correspondence should be addressed. E-mail: giulietta.riboldi@nyulangone.org

Editor: Elan D. Louis, Yale University, USA

Received: January 24, 2019; **Accepted:** March 4, 2019; **Published:** June 17, 2019

Copyright: © 2019 Riboldi & Frucht. This is an open-access article distributed under the terms of the Creative Commons Attribution–Noncommercial–No Derivatives License, which permits the user to copy, distribute, and transmit the work provided that the original authors and source are credited; that no commercial use is made of the work; and that the work is not altered or transformed.

Funding: None.

Financial Disclosures: None.

Conflict of Interest: The author reports no conflict of interest.

Ethics Statement: All the procedures reported in the manuscript were in accordance with the principles outlined in the Declaration of Helsinki. Written authorization for the acquisition and publication of the video for scientific purposes was obtained from the patient.

Introduction

Posthypoxic myoclonus (PHM) is a rare but severe and disabling condition, affecting a relatively young population.¹ First reported in 1939, it was described more systematically only in 1963 when Lance and Adams reported four patients who developed intention and action myoclonus after sudden hypoxic encephalopathy.² Since then, Lance–Adams syndrome (LAS), or chronic PHM, has been recognized as a well-defined clinical syndrome, where ataxia, dysarthria, and gait abnormalities are variably associated with intention, action, and/or stimulus-induced myoclonus.³ Usually, these neurologic symptoms improve slowly over time after the initial insult, while myoclonus may persist, frequently severely affecting the quality of life of patients who have otherwise recovered.¹ Classically, symptoms start within days or weeks after the causal event, usually a cardiopulmonary arrest. LAS can present as generalized or multifocal myoclonus, mainly affecting the limbs and interfering with fine motor skills. Negative myoclonus of the legs may be present, causing

inability to stand and a classic bouncing appearance when patients try to ambulate.

Myoclonus in PHM can be cortical or subcortical (reticular reflex myoclonus), and a combination of the two is often present in the same patient.⁴ Although the pathophysiologic understanding of PHM is incomplete, the serotonergic and the gamma-aminobutyric acid-ergic (GABAergic) systems seem to play a central role.^{5,6} Imaging and neurophysiological studies have been performed in order to characterize the drivers of PHM.^{7,8,9,10,11} Combined neurophysiological recording confirmed abnormal electrical activities usually with a cortical origin, mostly in the sensory motor area.¹² The electrical activity of electroencephalogram (EEG) and electromyography (EMG) recordings is usually inconsistently time-locked, and epileptic features such as polyspike and spike-wave activity are present in the majority of cases.¹³ However, imaging studies are suggestive of not only a cortical involvement that has been mainly reported in the frontal lobe, but also of the parietal and temporal lobes,

consistently with the involvement of the sensory motor area. Indeed, metabolic abnormalities and restricted diffusion were reported also in the cerebellum, thalamus, lenticular, and pontine nuclei.¹² Thus, it is possible that an impaired connectivity from subcortical areas is responsible for the abnormal cortical discharge that generates the myoclonus.

The treatment of PHM can be very challenging, limited by a paucity of class I trials and the rarity of the condition. According to the literature, clonazepam, valproic acid, and levetiracetam are the most effective treatments, usually used in combination.^{1,14} In refractory cases, administration of L-5-hydroxytryptophan (L-5-HTP), piracetam, lacosamide, zonisamide, and agomelatine has been used.^{15,16,17,18} Deep brain stimulation (DBS) has been attempted in multi-drug-resistant patients, with partially positive results upon targeting the globus pallidus internus (GPi).^{19,20,21,22} In refractory cases, sodium oxybate (SBX) has been used as well, with good results.

SBX is a sodium salt of γ -hydroxybutyrate that has been found to be effective in ameliorating alcohol-responsive movement disorders. Currently, it has been approved for the treatment of excessive daytime sleepiness and cataplexy in narcolepsy in the United States, and also for the treatment of alcohol dependency and acute alcohol withdrawal in some European countries. Promising results have been reported in patients with treatment-refractory alcohol-responsive movement disorders, such as myoclonus dystonia, essential tremor, spasmodic dysphonia, vocal tremor, and recently also for excessive daytime sleepiness in Parkinson's disease.^{23,24,25,26,27} The most common adverse events described with SBX use are excessive sedation, respiratory impairment, and depression.

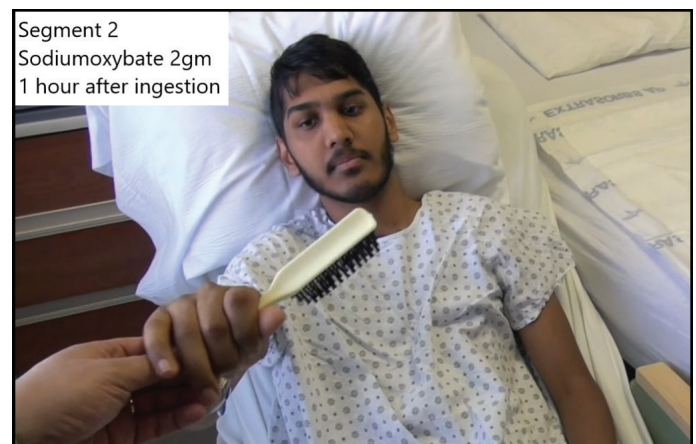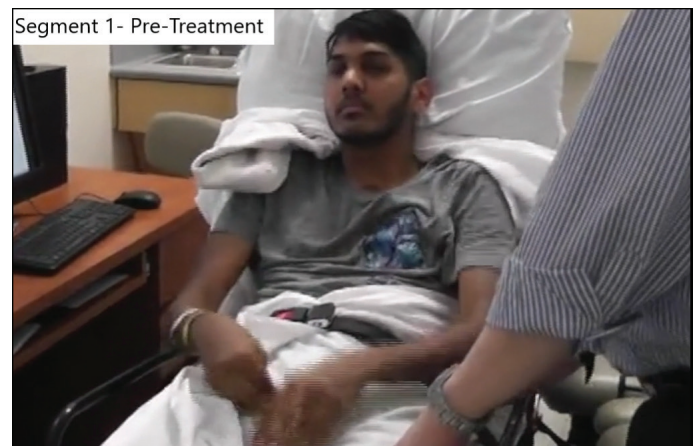The benefit of alcohol in LAS was first reported in 1992, but few cases have been described in the literature.²⁸ Here we report a new patient affected with PHM who was successfully treated with SBX. We also review our experience and cases reported in the literature comparing their clinical outcome measures. The purpose of this study is to bring together experience with SBX in PHM, as this drug represents a potentially important option for patients who are severely affected and refractory to treatment with other medications.

Case series

Case 1

A healthy 19-year-old man presented sudden shortness of breath after bilateral spontaneous pneumothorax. On his way to the hospital, he suffered a cardiac arrest and received cardiopulmonary resuscitation (CPR) for about 6 minutes in the ambulance. He was resuscitated and then admitted to the intensive care unit (ICU), where he developed seizures, autonomic storm, and continuous myoclonic jerks. Profound myoclonus at rest and with action persisted upon his awakening (Video 1, segment 1). Written informed consent was obtained for video recording. Brain magnetic resonance imaging (MRI) showed bilateral T2/FLAIR hyperintensity of putamen and caudate, with negative diffusion restriction. EEG showed severe generalized slowing, with no events correlating with his jerks. After 4 months, resting and kinetic myoclonic jerks were still present despite treatment with valproic acid (1,000 mg), levetiracetam (1,000 mg), and zolpidem (5 mg). Previously, he tried also lacosamide (300 mg) and clonazepam (4.5 mg). Myoclonus

was severely debilitating, to the point that he required a PEG tube for feeding. Based on the supposition that his myoclonus might be alcohol-responsive, he was admitted to the hospital for an observed initiation and titration with sodium oxybate (Xyrem). He was started on Xyrem 1 g and then gradually increased up to 1.5, 2, and 2.5 g. He showed a profound improvement in myoclonus in dose-dependent manner, experiencing benefit 30–45 minutes after dose administration. At 2 g, myoclonus at rest disappeared in 40 minutes, and he was able to sit calmly in the chair. Action myoclonus was still present, but he was able to hold and transfer objects, to brush and comb his hair, and to feed himself (Video 1, segment 2). At present, he continues on Xyrem 2 g four times daily. He responds to each dose within 30 minutes, with each dose lasting about 3 hours. He is slowly improving. He is now able to stand for a few seconds with assistance, and he is no longer PEG fed.



Video 1. Clinical Presentation of the Patient Described in the Paper before and after Treatment with SBX. The first part of the video documents our patient's baseline examination. There is prominent myoclonus at rest and with action. The second part of the video presents the clinical outcome after 1 hour of administration of SBX 2 g. Myoclonus at rest is abolished, and there is significant improvement of action myoclonus.

Table 1. Demographic and Clinical Features of the Patient Reported in This Study and Previous Cases Described in the Literature

| Reference number | Case number | AOO (y) | PHM onset (d) | Leading event | Duration of hypoxic event | Treatments | SBX (regimen) | Persistence of efficacy | Myoclonus Outcome | | | | Adverse events |
|------------------|-------------|---------|---------------|--------------------------------|---------------------------|--|-------------------|-------------------------|-------------------|------------------|-----------------|-----------|---|
| | | | | | | | | | Resting | Stimulus-induced | Action | Negative | |
| This case | 1 | 19 | <1 | Bilateral PNX | 6 min | VA (1,000 mg), LEV (1,000 mg), ZLP (5 mg) | 2 g QID | 3 hours | ↓↓ | ↓↓ | ↓ | ↓ | None |
| 26 | 2 | 34 | <1 | Anesthesia | NA | CZM, VA, PBT, TPM, ZNS, LEV | 2.5 g/4 hours | 3.5 hours | ↓↓ | ↓↓ | ↓ | No effect | dizziness |
| 25 | 3 | 31 | NA | Cardiac arrest – drug overdose | NA | LEV 2,500 mg, CZM 6 mg, PBT 60 mg, ALPZ 0.5 mg, rabeprazole 20 mg, BACL 20 mg, VA, TZ, PRM, GPT, PX, PIR | 2 g TID | 3.5–4 hours | ↓↓ | ↓↓ | ↓ | NA | HA, asthma, sedation and mild disinhibition |
| 30 | 4 | 61 | NA | NA | NA | CZM, LEV, ZNS | 2 g | NA | ↓ ^a | ↓↓ ^a | ↓↓ ^a | NA | NA |
| 30 | 5 | 39 | NA | NA | NA | CZM, VA, LEV | 2 g | NA | ↓ ^a | ↓↓ ^a | ↓↓ ^a | NA | NA |
| 30 | 6 | 62 | NA | NA | NA | CZM, LEV, ZNS, VA | 2 g | NA | ↓ ^a | ↓↓ ^a | ↓↓ ^a | NA | NA |
| 30 | 7 | 38 | NA | NA | NA | CZM, LEV, L-5-HTP, PBT, PIR, TPM, VA | 2 g | NA | ↓ ^a | ↓↓ ^a | ↓↓ ^a | NA | NA |
| 29 | 8 | 16 | 1 | Bilateral PNX | 7 minutes | PIR (36 g), LEV (4,000 mg), CZM (11.25 mg), VA (2,200 mg), 5-HTP (1,200 mg) | 2 g every 4 hours | NA | ↓↓ | ↓↓ | ↓ | No effect | Somnolence, GI distress |

Abbreviations: ALPZ, Alprazolam; AOO, age of onset; BACL, baclofen; CZM, clonazepam; GI, gastrointestinal; GPT, gabapentin; HA, headache; LEV, levetiracetam; NA, not available; PBT, phenobarbital; PIR, piracetam; PRM, primidone; PX, paroxetine; TPM, topiramate; TZ, tizanidine; VA, valproic acid; ZLP, zolpidem; ZNS, zonisamide.

^a Results expressed as average of cases reported in the paper.

Subsequently, he has undergone DBS of the GPi, with continued improvement.

Other cases

Published cases of PHM treated with SBX are summarized in Table 1.^{25,26,29,30} The mean age of onset of PHM was 40.1 years (range 16–62 years). In these patients, the leading event was represented by cardiac arrest, bilateral spontaneous pneumothorax, and anesthesia-induced hypoxia. In most instances, patients suffered a prolonged anoxic insult, up to 7 minutes. The onset of myoclonus usually occurred within 24 hours after the leading event, as soon as sedation was discontinued. Brain imaging was available only in two of the reported cases, showing mild atrophy in one patient (case 2), while hyperintensity of the basal ganglia (caudate, putamen, and pallidum) in T1- and T2-weighted images was present in the other case, as typically seen in hypoxic damage (case 8).

All patients, except case 4, were treated with levetiracetam, clonazepam, and valproic acid, plus a combination of other benzodiazepine (alprazolam), sedatives (zolpidem), antiepileptic drugs (e.g., phenobarbital, piracetam, topiramate, gabapentin, zonisamide, and primidone), and muscle relaxants (tizanidine and baclofen). Cases 7 and 8 were treated

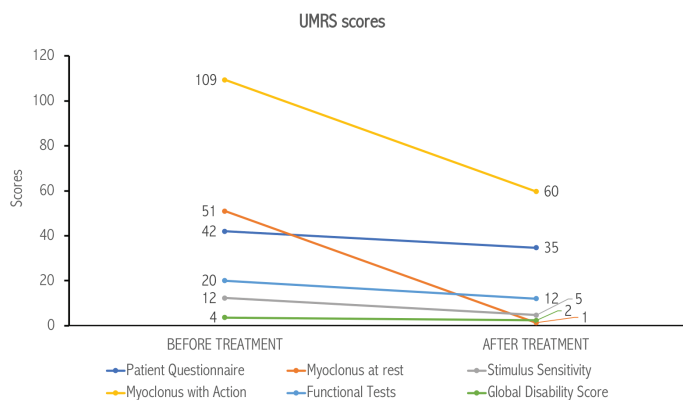


Figure 1. Graphic Representation of the Outcome Measure of the UMRS before and after Treatment with Sodium Oxybate (SBX). The average of the scores for the six sections of the UMRS was calculated from patient data available in the literature. Scores were calculated before and after treatment with the most effective dose of SBX for each patient. Pre- and post-treatment average scores are reported next to each vector. Subscore for each patient and dosages of SBX are reported in Table 2.

Table 2. Outcome Measures

| Reference | Patient Number in the Original Paper | Sodium Oxybate Dosage | | | | | |
|-------------------------------------|--------------------------------------|-----------------------|-----|-----|-------|-----|-----|
| | | 0 g | 1 g | 2 g | 2.5 g | 3 g | 4 g |
| Section 1 (Patient Questionnaire) | | | | | | | |
| 26 | 1 | 33 | / | 31 | / | 25 | 18 |
| 25 | 1 | 33 | / | / | / | 31 | / |
| 29 | 1 | 60 | 60 | 58 | 48 | / | / |
| Section 2 (Myoclonus at Rest) | | | | | | | |
| 26 | 1 | 21 | / | 8 | / | 3 | 1 |
| 25 | 1 | 3 | 3 | 0 | 0 | 3 | / |
| 29 | 1 | 128 | 120 | 41 | 0 | / | / |
| Section 3 (Stimulus Sensitivity) | | | | | | | |
| 26 | 1 | 12 | / | 5 | / | 1 | 1 |
| 25 | 1 | 8 | 3 | 1 | 2 | 3 | / |
| 29 | 1 | 17 | 17 | 15 | 10 | / | / |
| Section 4 (Myoclonus with Action) | | | | | | | |
| 26 | 1 | 108 | / | 70 | / | 64 | 53 |
| 25 | 1 | 108 | 96 | 64 | 54 | 86 | / |
| 29 | 1 | 112 | 112 | 66 | 40 | / | / |
| Section 5 (Functional Tests) | | | | | | | |
| 26 | 1 | 20 | / | 10 | / | 8 | 7 |
| 25 | 1 | 20 | 20 | 13 | 12 | 15 | / |
| 29 | 1 | 20 | 20 | 19 | 14 | / | / |
| Section 6 (Global Disability Score) | | | | | | | |
| 26 | 1 | 3 | / | 2 | / | 2 | 2 |
| 25 | 1 | 4 | 3 | 3 | 2 | 3 | / |
| 29 | 1 | 4 | 4 | 4 | 2 | / | / |

Note: Scores for the different sections of the Unified Myoclonus Rating Scale (UMRS) that were available in the literature are reported in the table. Different doses of SBX were tested in each patient. The scores for the different dosages administered to each patient are reported. Section 1 (patient questionnaire): range 0–44; Section 2 (myoclonus at rest): range 0–108; Section 3 (stimulus sensitivity): range 0–17; Section 4 (myoclonus with action): range 0–160; Section 5 (functional tests): range 0–28; Section 6 (global disability score): range 0–4.

also with 5-hydroxytryptophane while in another case (case 3) paroxetine was attempted. Despite these various combinations of treatments, myoclonus remained refractory and severe. In seven out of eight patients (cases 2–7), symptoms were alcohol responsive. The treatment refractory nature and alcohol responsiveness lead to the decision to try SBX.

In all patients, myoclonus was noted to improve in dose-dependent manner. The results were evaluated in the majority of the cases through standardized scales (i.e., Unified Myoclonus Rating Scale – UMRS) and review of videos³¹ (Figure 1). Stimulus-induced myoclonus significantly decreased in all cases, while improvement in resting and action myoclonus varied between patients (Table 2). Negative myoclonus was less

responsive to treatment, although physiologic confirmation of this effect was lacking. SBX was slowly titrated in all patients, increasing each dose by 0.5–1 g every 2 weeks in order to maximize the tolerability of the medication, reduce adverse events, and establish the minimally effective dose. The average dose required by this cohort of patients was 2 g three to four times daily, with the effect of each dose lasting for 3–4 hours on average. Latency from the onset of myoclonus to treatment did not seem to affect the efficacy of the treatment. No serious adverse events were reported, while asthma and sedation were reported in few cases (cases 2 and 3). All patients and their caregivers were aware of the kinetics of the medication.

Discussion

After posthypoxic insult, severe and debilitating myoclonus can be present in 30–40% cases and can severely affect the quality of life of those who survive life-threatening cardiopulmonary arrests.²⁹ The treatment of PHM is often challenging. Patients often recover their cognitive abilities, and they and their families experience significant frustration and anxiety over the unpredictability and empiric nature of available treatments. Patience is required to titrate and adjust medication dosing in order to find a combination that will best address individual patient's needs.³² Of available treatments, antiepileptic drugs, benzodiazepines, L-5-HTP, agomelatine, and GPi DBS have been attempted with promising results.³² However, some cases of PHM can be resistant to available combinations of medications. SBX may represent a promising option for these treatment refractory patients.

SBX is a precursor of GABA that easily crosses the blood–brain barrier and modulates the GABA-A receptors.³³ Our patient experienced improvement in resting and stimulus-induced myoclonus, and moderate improvement in action myoclonus, allowing him to regain a satisfactory degree of autonomy in many of his daily activities (such as eating, washing himself, and manipulating small objects, as well as standing) that were completely lost prior to treatment. Other patients reported in the literature have experienced similar benefit.^{25,29,30}

We are aware of the open-label nature of this experience, with the inherent bias for placebo response. Nevertheless, the often-dramatic nature of the response and the clear pharmacokinetics support the potential efficacy of SBX in PHM. In our opinion, SBX should not be used as a first-line agent in PHM, as many patients will obtain adequate benefit from available medications such as clonazepam, levetiracetam, valproic acid, and zonisamide. In patients who do not respond to these agents, SBX may be proposed as a possible treatment. In all the cases reported in the literature, SBX was initially tested as an add-on treatment. Should SBX be effective, discontinuation or dosage modification of other medications can be considered, especially in case of side effects. However, in the majority of cases, patients with PHM will remain on polytherapy. An observed alcohol challenge can be very helpful in documenting responsiveness, and also convincing the patient's family and care team about the merit of this approach. However, this is not strictly required in order to start the treatment with SBX. Indeed, in severely refractory patients with PHM, in the attempt to better treat patients' symptoms it should be worth considering SBX even if an alcohol responsiveness has not been clearly documented. Wherever possible, videotaped evaluations using the UMRS should be performed before and 1 hour after dose initiation in order to document tolerability and efficacy. Starting with a twice-daily dose regimen is wise, at low dose (1 g per dose). In the hospital setting, individual dosing can be increased quickly, even daily, by 0.5 g increments. If the response is robust, and tolerability is satisfactory, dosing can be changed to thrice daily. Long-term use generally is characterized by continuation in prior efficacy and tolerability. In patients who are still severely disabled by myoclonus, SBX may be used as a bridge to consider more invasive treatments, such as deep brain stimulation.

We are aware of the limitation of the reported observations given the small number of subjects of this cohort and the lack of placebo-controlled trials. However, the outcomes of the reported cases are very promising, and they should open the way for further studies with larger cohort of subjects in order to better define the extent of the response to SBX in PHM and formulate guidelines.

References

1. Frucht S, Fahn S. The clinical spectrum of posthypoxic myoclonus. *Mov Disord* 2000;15 Suppl 1:2–7.
2. Lance JW, Adams RD. The syndrome of intention or action myoclonus as a sequel to hypoxic encephalopathy. *Brain* 1963;86:111–36.
3. Espay AJ, Chen R. Myoclonus. *Continuum* 2013;19(5 Movement Disorders):1264–1286.
4. Hallett M. Physiology of human posthypoxic myoclonus. *Movement Disorders* 2000;15 Suppl 1:8–13.
5. Welsh JP, Placantonakis DG, Warsetsky SI, Marquez RG, Bernstein L, Aicher SA. The serotonin hypothesis of myoclonus from the perspective of neuronal rhythmicity. *Adv Neurol* 2002;89:307–329.
6. Matsumoto RR, Truong DD, Nguyen KD, Dang AT, Hoang TT, Vo PQ, et al. Involvement of GABA(A) receptors in myoclonus. *Mov Disord* 2000;15 Suppl 1:47–52.
7. Zhang YX, Liu JR, Jiang B, Liu HQ, Ding MP, Song SJ, et al. Lance-Adams syndrome: a report of two cases. *J Zhejiang Univ Sci B* 2007;8(10):715–720.
8. Park KM, Han YH, Kim TH, Mun CW, Shin KJ, Ha SY, et al. Increased functional connectivity between motor and sensory cortex in a patient with Lance-Adams syndrome. *Clin Neurol Neurosurg* 2015;139:241–243.
9. Lee HL, Lee JK. Lance-adams syndrome. *Ann Rehabil Med* 2011;35(6):939–943.
10. Hiramoto N, Shime N, Kageyama K, Ashida H, Itoi T, Tanaka Y. Intention myoclonus in paediatric patients following severe cardiopulmonary failure: a report of three cases. *Crit Care Resusc* 2002;4(2):104–106.
11. Frucht SJ, Trost M, Ma Y, Eidelberg D. The metabolic topography of posthypoxic myoclonus. *Neurology* 2004;62(10):1879–1881.
12. Gupta HV, Caviness JN. Post-hypoxic Myoclonus: current concepts, neurophysiology, and treatment. *Tremor Other Hyperkinet Mov* 2016;6:409.
13. Freund B, Sutter R, Kaplan PW. Lance-Adams syndrome in the pretargeted temperature management era. *Clin EEG Neurosci* 2017;48(2):130–138.
14. Frucht SJ, Louis ED, Chuang C, Fahn S. A pilot tolerability and efficacy study of levetiracetam in patients with chronic myoclonus. *Neurology* 2001;57(6):1112–1114.
15. Striano P, Manganello F, Boccella P, Perretti A, Striano S. Levetiracetam in patients with cortical myoclonus: a clinical and electrophysiological study. *Mov Disord* 2005;20(12):1610–1614.
16. Polesin A, Stern M. Post-anoxic myoclonus: a case presentation and review of management in the rehabilitation setting. *Brain Inj* 2006;20(2):213–217.
17. Gonzalez de la Aleja J, Saiz-Diaz RA, De la Pena P. Relief of intractable posthypoxic myoclonus after administration of agomelatine. *Clin Neuropharmacol* 2012;35(5):258–259.
18. Galldiks N, Timmermann L, Fink GR, Burghaus L. Posthypoxic myoclonus (Lance-Adams syndrome) treated with lacosamide. *Clin Neuropharmacol* 2010;33(4):216–217.

19. Yamada K, Sakurama T, Soyama N, Kuratsu J. Gpi pallidal stimulation for Lance-Adams syndrome. *Neurology* 2011;76(14):1270–1272.
20. Ramdhani RA, Frucht SJ, Kopell BH. Improvement of post-hypoxic myoclonus with bilateral pallidal deep brain stimulation: a case report and review of the literature. *Tremor Other Hyperkinet Mov* 2017;7:461.
21. Kobayashi K, Katayama Y, Otaka T, Obuchi T, Kano T, Nagaoka T, et al. Thalamic deep brain stimulation for the treatment of action myoclonus caused by perinatal anoxia. *Stereotact Funct Neurosurg* 2010;88(4):259–263.
22. Asahi T, Kashiwazaki D, Dougu N, Oyama G, Takashima S, Tanaka K, et al. Alleviation of myoclonus after bilateral pallidal deep brain stimulation for Lance-Adams syndrome. *J Neurol* 2015;262(6):1581–1583.
23. Rumbach AF, Blitzer A, Frucht SJ, Simonyan K. An open-label study of sodium oxybate in Spasmodic dysphonia. *Laryngoscope* 2017;127(6):1402–1407.
24. Priori A, Bertolasi L, Pesenti A, Cappellari A, Barbieri S. gamma-hydroxybutyric acid for alcohol-sensitive myoclonus with dystonia. *Neurology* 2000;54(8):1706.
25. Frucht SJ, Bordelon Y, Houghton WH, Reardan D. A pilot tolerability and efficacy trial of sodium oxybate in ethanol-responsive movement disorders. *Mov Disord* 2005;20(10):1330–1337.
26. Frucht SJ, Bordelon Y, Houghton WH. Marked amelioration of alcohol-responsive posthypoxic myoclonus by gamma-hydroxybutyric acid (Xyrem). *Mov Disord* 2005;20(6):745–751.
27. Buchele F, Hackius M, Schreglmann SR, Omlor W, Werth E, Maric A, et al. Sodium Oxybate for excessive daytime sleepiness and sleep disturbance in Parkinson disease: a randomized clinical trial. *JAMA Neurol* 2018;75(1):114–118.
28. Genton P, Guerrini R. Effect of alcohol on action myoclonus in Lance-Adams syndrome and progressive myoclonus epilepsy. *Mov Disord* 1992;7(1):92.
29. Arpesella R, Dallochio C, Arbasino C, Imberti R, Martinotti R, Frucht SJ. A patient with intractable posthypoxic myoclonus (Lance-Adams syndrome) treated with sodium oxybate. *Anaesth Intensive Care* 2009;37(2):314–318.
30. Frucht SJ, Houghton WC, Bordelon Y, Greene PE, Louis ED. A single-blind, open-label trial of sodium oxybate for myoclonus and essential tremor. *Neurology* 2005;65(12):1967–1969.
31. Frucht SJ, Leurgans SE, Hallett M, Fahn S. The Unified Myoclonus Rating Scale. *Adv Neurol* 2002;89:361–376.
32. Levy A, Chen R. Myoclonus: pathophysiology and treatment options. *Curr Treat Options Neurol* 2016;18(5):21.
33. Waszkielewicz A, Bojarski J. Gamma-hydroxybutyric acid (GHB) and its chemical modifications: a review of the GHBergic system. *Pol J Pharmacol* 2004;56(1):43–49.