

Brief Reports

The Effect of Botulinum Toxin on Network Connectivity in Cervical Dystonia: Lessons from Magnetoencephalography

Abhimanyu Mahajan^{1*}, Abdullah Alshammaa¹, Andrew Zillgitt¹, Susan M. Bowyer¹, Peter LeWitt¹, Patricia Kaminski¹ & Christos Sidiropoulos^{1,2}

¹ Department of Neurology, Henry Ford Hospital, Detroit, MI, USA, ² Department of Neurology and Ophthalmology, Michigan State University, East Lansing, MI, USA

Abstract

Background: Pharmacological management of cervical dystonia (CD) is considered to be symptomatic in effect, rather than targeting the underlying pathophysiology of the disease. Magnetoencephalography (MEG), a direct measure of neuronal activity, while accepted as a modality for pre-surgical mapping in epilepsy, has never been used to explore the effect of pharmacotherapy in movement disorders.

Methods: Resting state MEG data were collected from patients with CD, pre- and post-botulinum toxin injections. All of these patients exhibited good clinical benefit with botulinum toxin. Resting state MEG data from four age- and gender-matched healthy controls with no neurological disorders were also collected.

Results: Our exploratory study reveals a difference in coherence between controls and patients in the following regions: fronto-striatal, occipito-striatal, parieto-striatal, and striato-temporal networks. In these regions there is an increase after botulinum toxin. Specifically, increased coherence in the left putamen and right superior parietal gyrus was noticeable. Both intrahemispheric and interhemispheric networks were affected.

Discussion: This is the first attempt to directly assess changes in functional connectivity with pharmacotherapy using MEG. Botulinum toxin might affect sensorimotor integration, leading to clinical benefit. The presence of increased interhemispheric coherence and intrahemispheric coherence points to the importance of global and local networks in the pathophysiology of dystonia.

Keywords: Cervical dystonia, functional imaging, magnetoencephalography, botulinum toxin, sensorimotor integration

Citation: Mahajan A, Alshammaa A, Zillgitt A, Bowyer SM, LeWitt P, Kaminski P, et al. The effect of botulinumtoxin on network connectivity in cervical dystonia: lessons from magnetoencephalography. Tremor Other Hyperkinet Mov. 2017; 7. doi: 10.7916/D84M9H4W

*To whom correspondence should be addressed. E-mail: amahajal@hfhs.org

Editor: Elan D. Louis, Yale University, USA

Received: August 10, 2017 **Accepted:** October 23, 2017 **Published:** November 10, 2017

Copyright: © 2017 Mahajan et al. This is an open-access article distributed under the terms of the Creative Commons Attribution–Noncommercial–No Derivatives License, which permits the user to copy, distribute, and transmit the work provided that the original authors and source are credited; that no commercial use is made of the work; and that the work is not altered or transformed.

Funding: None.

Financial Disclosures: None.

Conflicts of Interest: The authors report no conflicts of interest.

Ethics Statement: This study was performed in accordance with the ethical standards detailed in the Declaration of Helsinki. The authors' institutional ethics committee has approved this study and all patients have provided written informed consent.

Introduction

Dystonia is described as a varied pattern of sustained involuntary movement characterized by overactivity of muscles, often associated with voluntary movement. While the etiology may be initially attributed to a psychiatric condition, it is now clear this is a movement disorder. In fact, in 1986 abnormal activity in the basal ganglia-thalamocortical circuits was proposed as the underlying pathogenesis of disorders of motor function.¹ More recently, studies have indicated that reduced intracortical inhibition and distorted somatotopic cortical representation in the somatosensory cortex play a critical role in the

pathogenesis of dystonia.² Using fludeoxyglucose positron emission tomography (FDG-PET) and diffusion tensor imaging (DTI), Carbon et al.³ described aberrant fronto-striatal connectivity and cerebellar involvement in the disease mechanism of hereditary dystonia. Other studies using functional MRI (fMRI) in cervical dystonia (CD) patients revealed altered functional connectivity within the sensorimotor, the executive control, and the primary visual networks.⁴

While there is no known cure for dystonia, medications can often reduce the sustained contraction, thereby providing relief. Pharmacological management of dystonia, including muscle relaxants, botulinum

toxin injections, and benzodiazepines are thought to be symptomatic in effect, rather than targeting the underlying pathophysiology of the disease.⁵

Magnetoencephalography-coherence source imaging (MEG-CSI) has primarily been studied for pre-surgical mapping in patients with focal epilepsy, with better surgical outcomes with use.⁶ It has never been utilized in patients with dystonia.

In our study, we aimed to characterize functional connectivity in patients with CD before and after treatment with botulinum toxin, using MEG-CSI.

Methods

MEG data were collected from four patients, between the ages of 33 and 61 years, with CD (Table 1). These patients had to exhibit good clinical benefit with botulinum toxin injections to be included in this study. Patients were asked about the maximal benefit they experienced from the botulinum toxin before scheduling them for a MEG study post injection. On average, this was between 2 and 3 weeks post injection. MEG data from four age- and gender-matched controls with no diagnosed neurological disorder were also collected.

Resting state MEG data were acquired for 10 minutes with eyes open, using a 148-channel whole-head magnetometer system (4D Neuroimaging, San Diego, CA) inside a magnetically shielded room. Two 10-minute MEG scans were obtained per patient: one pre- and one post medication. The data were sampled at a rate of 508.6 Hz (DC to 100 Hz, with direct coupling at zero Hz) and then were forward and backward bandpass filtered (3–50 Hz). Changes in the subject's position during the study were detected by alterations in the magnetic field locations from five coils on the forehead and in front of both ears.⁵ An independent component analysis (ICA) was used to filter out the identifiable heart signals observed in the MEG recordings. Then, MEG-CSI was performed to assess neuronal synchrony within different brain regions.⁷ Post-acquisition data processing was performed using MEG Tools, an open-source Matlab-based (Mathworks Inc., Natick, MA, USA) software module for cortical source imaging.

MEG-CSI results were displayed on the patient's MRI scan, which was co-registered to the subject's digitized head shape recorded at the time of MEG data collection. To localize sources of coherent activity, a model of gray matter was constructed using the individual's T1-weighted high-resolution volumetric MRI scan. The realistic head model consisted of X-, Y-, and Z-oriented dipoles at approximately 4,000 locations distributed to represent the same amount of gray matter identified in each individual's MRI scan. Synchronization of neuronal activity was quantified by applying a time frequency decomposition technique, the short-time Fourier transformation (sFFT). After transformation to a time frequency representation, the strength of network interactions was estimated by calculating coherence, a measure of synchrony between signals from different brain regions for each FFT frequency component. The 10 minutes of resting state MEG data were prepared for source imaging by division into 80 segments, each containing 7.5 seconds of data of relatively uniform brain behavior.⁷ For each of these data segments, signals from neuronal sources were isolated using another ICA spatiotemporal decomposition technique designed to extract signals from distinct compact sources that exhibit burst behavior and minimal temporal overlap with other active sources. These ICA signal components have MEG spatial magnetic field patterns corresponding to one or a few spatially distinct compact sources that are much easier to image accurately using a current distribution source imaging technique (MR-FOCUSS).⁶ Separate from the imaging algorithm, the cross-spectrum between ICA signals was calculated. In these cross-spectrum calculations, a sequence of FFT spectra was calculated using 0.5 second windows and 25% overlap with FFT amplitudes for 24 frequency bins of 2 Hz width between 3 and 50 Hz. The imaging results and the signal cross-spectrum were used to calculate the coherence between all pairings (1,431 locations in the brain) of active cortical locations within each of 24 frequency bins. Finally, for each active source, the average coherence across frequencies and sources was calculated. In these coherence imaging results, the localization of imaged brain activity is strongly dependent on the frequency bands with greatest power. Coherence analysis results were

Table 1. Patient Demographics and Clinical Characteristics

	Patient 1	Patient 2	Patient 3	Patient 4
Age (years)	54	61	53	33
Gender	Male	Female	Female	Female
Disease duration (years)	3	21	1	1
Diagnosis	Cervical dystonia	Cervical dystonia	Cervical dystonia	Cervical dystonia
Pharmacotherapy	Botulinum toxin type A	Botulinum toxin type A	Botulinum toxin type A	Botulinum toxin type A
Description of cervical dystonia	“Right laterocollis with right shoulder elevation”	“Left dystonic neck, left torticollis, right laterocollis”	“Slight right laterocollis and slight anterocollis”	“Right torticollis, mild anterocollis and mild right laterocollis with right shoulder elevation”

encoded as a color spectrum for values between 1 (entirely coherent) and 0 (no coherence) and overlaid on the patient's MRI with the solutions restricted to the gray matter. A region-of-interest tool was used to identify 54 regions in the brain (27 in each hemisphere), using delineated anatomical structures. Anatomical identification in these regions was implemented using MEG tools.⁸ Coherence results were assessed within a given hemisphere (intra-hemispheric) and between the two hemispheres (inter-hemispheric).

A p-value was produced for each region pair. The false discovery rate (FDR) was used to adjust for multiple testing. Only statistically significant coherence values ($p < 0.05$) with a large effect were considered.

Further, to control for the FDR, the Benjamini–Hochberg (BH)-adjusted p-value was obtained.

This study was performed in accordance with the ethical standards laid down in the 1964 Declaration of Helsinki and its later amendments. All persons gave their written informed consent prior to their inclusion in the study. No patient-identifiable information was included in the text.

Results

Pre- and post-treatment MEG data were obtained in our four patients (Table 1, Figure 1). None of these patients was naïve to botulinum toxin at the time of the study. Prior to treatment, out of a total of 1,431 networks,

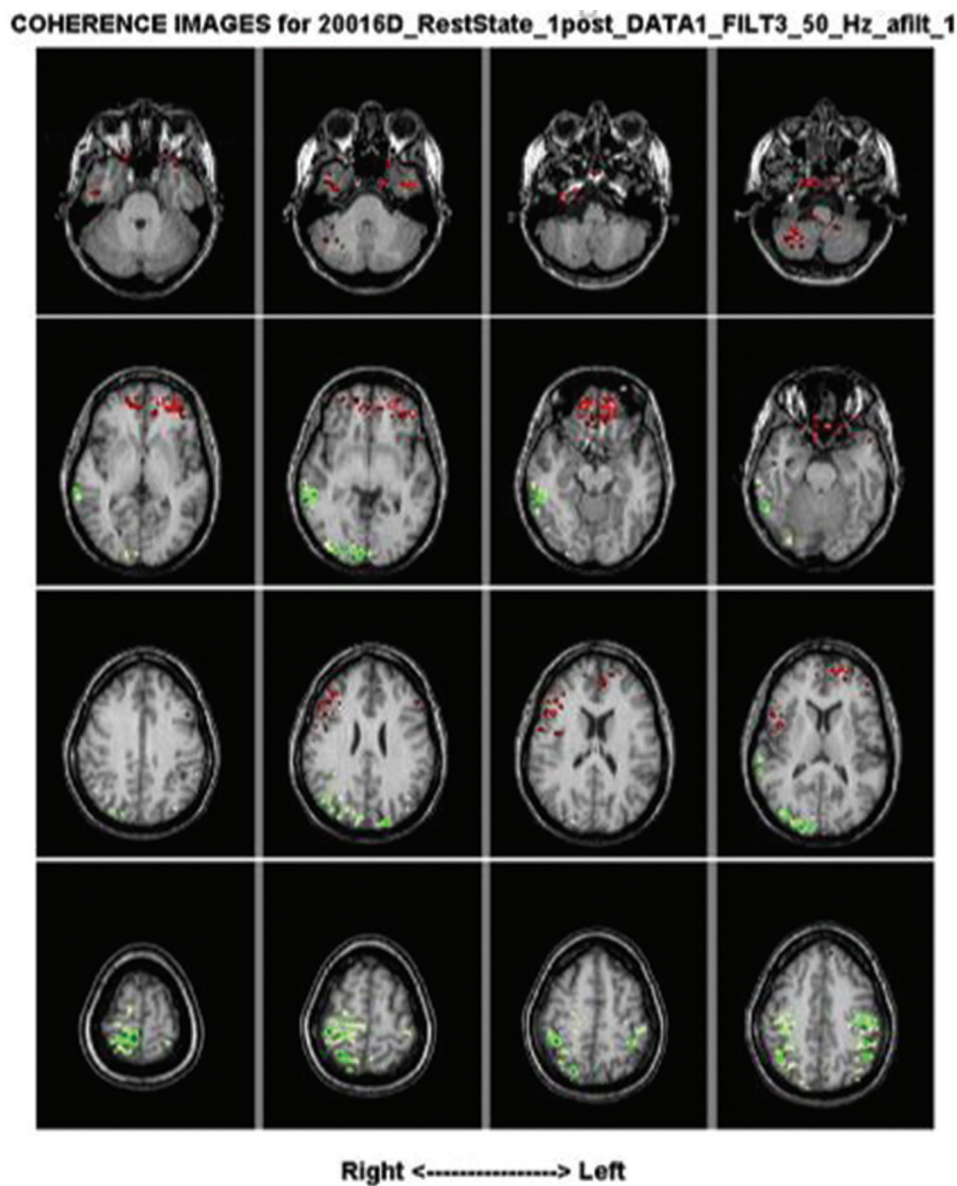


Figure 1. Patient 1, MEG Images Pre and Post Botulinum Toxin. Regions of the brain that are different pre (green) and post (red) medication in this subject who took botulinum toxin. Red areas indicate where more coherent activity was seen after treatment. Green areas had higher coherence prior to treatment.

11 interhemispheric networks and seven left-sided intrahemispheric networks were statistically significantly different between the two groups in the fronto-striatal pathway. Other pathways with a statistically significant difference in coherence between controls and patients were the occipito-striatal, parieto-striatal, and temporo-striatal areas, with areas of high coherence in the interhemispheric and intrahemispheric pathways (Figure 2).

After treatment, out of a total of 1,431 networks, 12 interhemispheric networks and eight left-sided intrahemispheric networks were statistically significantly different between the two groups in the fronto-striatal pathway. Other pathways with a statistically significant difference in coherence between controls and patients were again found in the occipito-striatal, parieto-striatal, and temporo-striatal regions, with the areas of high coherence in the interhemispheric and intrahemispheric pathways (Figure 2).

With botulinum toxin, an overall increase in coherence was seen in patients. Specifically, an increase was appreciated in each of the above-mentioned networks. Comparing coherence in CD patients pre- and post botulinum toxin, an increase was appreciated in the frontal–frontal, frontal–parietal, frontal–temporal, and cingulate–occipital pathways with botulinum toxin (Figure 2).

With BH adjustment, significant differences in coherence between controls and patients were seen in the following areas, prior to botulinum toxin injections: left cingulate gyrus–left putamen, left putamen–right inferior frontal gyrus, and left putamen–right inferior occipital gyrus (Figure 3). With botulinum toxin, significant differences in coherence between controls and patients was seen in the above-mentioned areas, along with an additional region of difference in coherence: the left putamen–right superior parietal gyrus (Figure 3).

Discussion

To our knowledge, this is the first study using MEG to explore functional networks in patients with CD. It is also the first MEG study to assess the effect of botulinum toxin on these networks.

Botulinum toxin is believed to have a symptomatic benefit in dystonia with no effect on the underlying pathophysiology. Our exploratory study reveals increased overall coherence, specifically in the fronto-striatal, occipito-striatal, parieto-striatal, and striato-temporal networks following treatment. Comparing coherence in CD patients, an increase was appreciated in the frontal–frontal, frontal–parietal, frontal–temporal, and cingulate–occipital pathways. These results may indicate a central mechanism to the clinical benefit. In addition, the presence of increased interhemispheric coherence, apart from intrahemispheric coherence, perhaps points toward the importance of global and local networks in the pathophysiology of dystonia.

Several studies have suggested the fronto-striatal network is associated with executive function while the occipito-striatal network represents visuospatial function.^{1,3,4} In our study, the difference in coherence, prior to botulinum toxin, between controls and patients was seen in the above-mentioned cortico-striatal pathways. This may indicate the underlying pathophysiology of CD.

The importance of executive dysfunction in movement disorders is well recognized.⁹ In fact, recent studies have expanded the understanding of visuospatial cognitive dysfunction in the pathology of dystonia, albeit with other neuroimaging modalities.^{3,4,10} While our study is not powered to comment on individual cognitive pathways in CD, this should be looked into in future studies.

In our clinical applications for epilepsy pre-surgical mapping, we found that using a 3 Hz high pass filter removes any breathing artifacts. We also found that using a 50 Hz low pass filter provides all the power in the data without any impact from the 60 Hz power lines. Future studies could open up the filter to a low pass of 100 Hz to determine if there is anything in the high gamma range that is different from that reported here.

BH adjustment of p-values lowers the false-positive rate and, therefore, allows for more stringent assessment of statistically significant coherence between two regions. With botulinum toxin, coherence between CD patients and controls became statistically significant in the following regions: left putamen and right superior parietal gyrus. The superior parietal lobule integrates multiple sensory inputs into a single spatial frame. It is associated with multisensory-motor integration and spatial attention in humans.¹¹ Our analysis indicates that the clinical benefit seen with botulinum toxin in CD patients might relate to improvement of sensorimotor integration.

Other studies have employed MEG to study dystonia. In a recent report assessing focal dystonia, patients showed reduced efficiency of inhibition in sensory areas. Further MEG analysis demonstrated decreased responsiveness to sensory thalamocortical inflow in primary and cortical areas.¹² In another MEG dystonia study, MEG revealed abnormal somatosensory reorganization in musician's dystonia.¹³ Our study is unique in that it utilized MEG-CSI to evaluate treatment responses in CD.

MEG offers several advantages when assessing functional cortical networks. Specifically, MEG is a direct measurement of neuronal activity with high temporal and spatial resolution. Unlike MEG using sensor space, MEG-CSI using source space localization does indeed have great spatial resolution for cortical imaging.¹⁴ Our source space coherence is performed after current distribution imaging has been performed. This negates the issue of current spread that would be the reason for poor spatial resolution of sensor space coherence. Our MEG laboratory sensor is a magnetometer-type system that is found to have better resolution for deeper structures.

Other functional neuroimaging studies such as positron emission tomography and fMRI may offer high spatial resolution but they are indirect measurements of brain activity—specifically, changes in metabolic responses and blood flow, respectively. These indirect measurements may offer less precise temporal resolution.

Although these results have illustrated changes in functional networks pre- and post-botulinum toxin, with the small sample size it is not feasible to comment on potential variation in the mechanism of action of the three treatment regimens used in this study. Further, our study does not employ validated rating scales to quantify the above-mentioned change in motor and potentially non-motor functionality

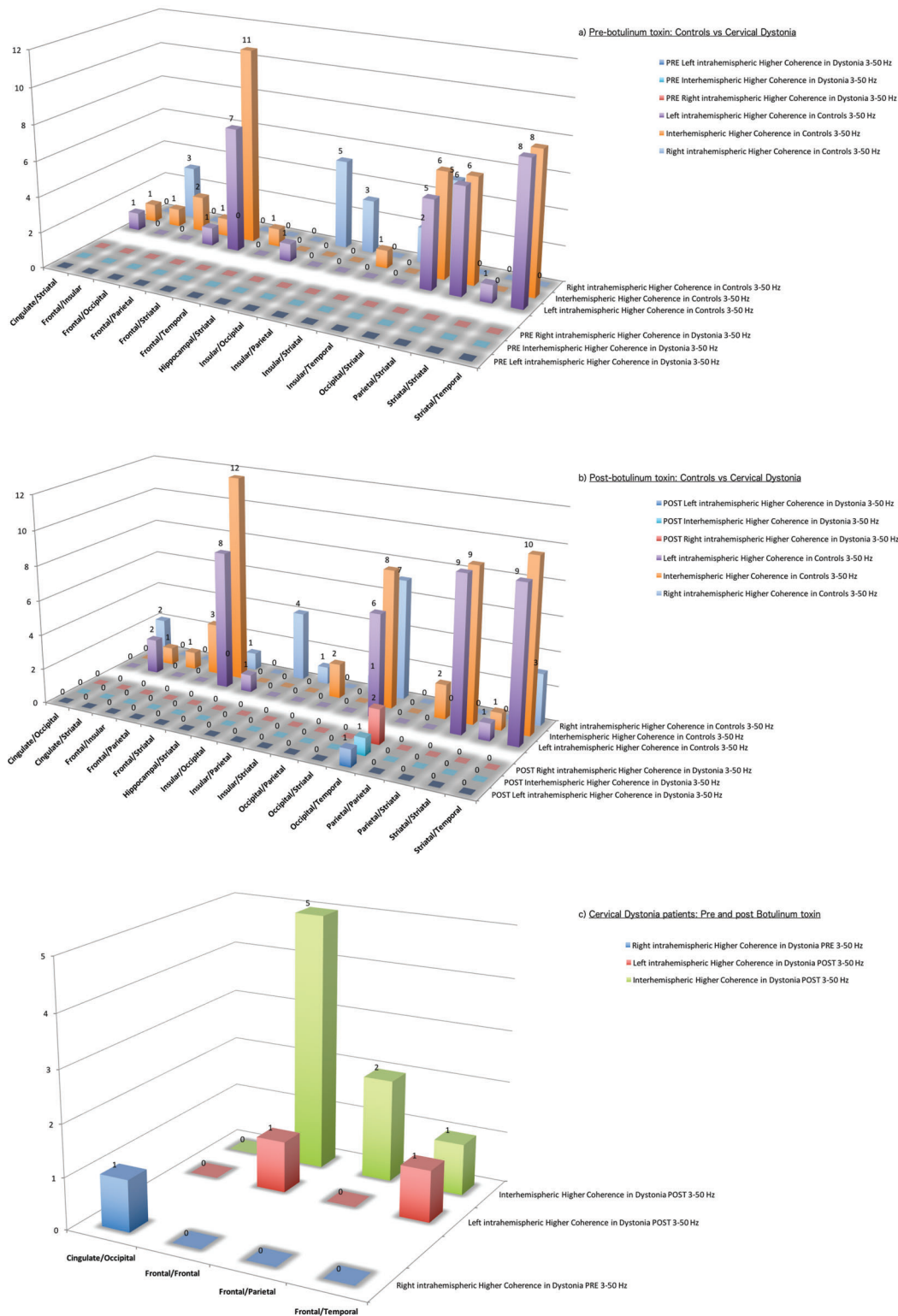


Figure 2. Difference in Coherence between Patients and Controls, Pre and Post-Botulinum Toxin. (A) The biggest difference in coherence seen in the fronto-striatal, occipito-striatal, parieto-striatal, and temporo-striatal areas in controls compared with patients. (B) With botulinum toxin, there is an increase in coherence overall in the above-mentioned pathways in controls compared with patients. (C) Comparing cervical dystonia patients, coherence networks increased after medication, especially in the frontal–frontal, frontal–parietal, frontal–temporal, and cingulate–occipital pathways.

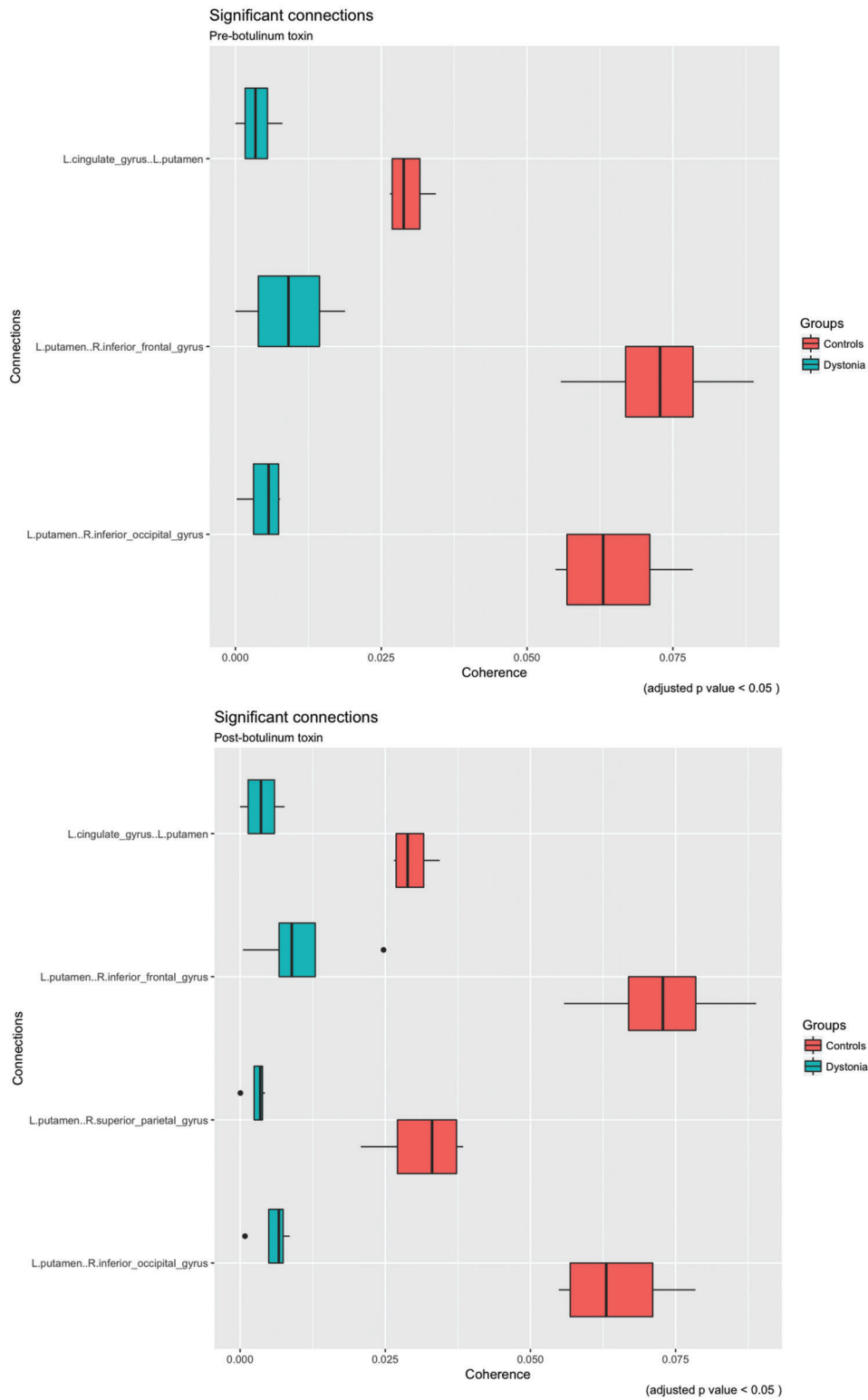


Figure 3. Difference in Coherence between Patients and Controls, Pre and Post Botulinum Toxin, using BH Correction. Using Benjamini–Hochberg adjustment, significant differences in coherence between patients and controls were seen in the following regions: left cingulate gyrus–left putamen, left putamen–right inferior frontal gyrus, left putamen–right inferior occipital gyrus. With botulinum toxin, additionally, a significant difference was seen in the left putamen–right superior parietal gyrus.

with botulinum toxin injections. While 1,431 network connections were assessed per patient using MEG, repetition of results with a larger sample size would be ideal to explore potential differences between medications with varying mechanisms of action.

References

1. Poston KL, Eidelberg D. Functional brain networks and abnormal connectivity in the movement disorders. *Neuroimage* 2012;62:2261–2270. doi: 10.1016/j.neuroimage.2011.12.021
2. Patel N, Hanfelt J, Marsh L, Jankovic J. Alleviating manoeuvres (sensory tricks) in cervical dystonia. *J Neurol Neurosurg Psychiatry* 2014;85:882–884. doi: 10.1136/jnnp-2013-307316
3. Carbon M, Argyelan M, Eidelberg D. Functional imaging in hereditary dystonia. *Eur J Neurol* 2010;17(Suppl. 1):58–64. doi: 10.1111/j.1468-1331.2010.03054.x
4. Delnooz CC, Pasma JW, Beckmann CF, van de Warrenburg BP. Task-free functional MRI in cervical dystonia reveals multi-network changes that partially normalize with botulinum toxin. *PLoS One* 2013;8:e62877. doi: 10.1371/journal.pone.0062877
5. Thenganatt MA, Jankovic J. Treatment of dystonia. *Neurotherapeutics* 2014;11:139–152. doi: 10.1007/s13311-013-0231-4
6. Elisevich K, Shukla N, Moran JE, Smith B, Schultz L, Mason K, et al. An assessment of MEG coherence imaging in the study of temporal lobe epilepsy. *Epilepsia* 2011;52:1110–1119. doi: 10.1111/j.1528-1167.2011.02990.x
7. Bowyer SM, Mason K, Tepley N, Smith B, Barkley GL. Magnetoencephalographic validation parameters for clinical evaluation of interictal epileptic activity. *J Clin Neurophysiol* 2003;20:87–93. doi: 10.1097/00004691-200304000-00001
8. Nazem-Zadeh MR, Bowyer SM, Moran JE, Davoodi-Bojd E, Zillgitt A, Weiland BJ, et al. MEG coherence and DTI connectivity in mTLE. *Brain Topogr* 2016;29:598–622. doi: 10.1007/s10548-016-0488-0
9. Mahajan A, Deal JA, Carlson M. Interventions in Parkinson's disease: role of executive function. *Front Biosci (Landmark Ed)* 2017;22:416–427. doi: 10.2741/4492
10. Filip P, Gallea C, Lehericy S, Bertasi E, Popa T, Mareček R, et al. Disruption in cerebellar and basal ganglia networks during a visuospatial task in cervical dystonia. *Mov Disord* 2017;32:757–768. doi: 10.1002/mds.26930
11. Molholm S, Sehatpour P, Mehta AD, Shpaner M, Gomez-Ramirez M, Ortigue S, et al. Audio-visual multisensory integration in superior parietal lobule revealed by human intracranial recordings. *J Neurophysiol* 2006;96:721–729. doi: 10.1152/jn.00285.2006
12. Tecchio F, Melgari JM, Zappasodi F, Porcaro C, Milazzo D, Cassetta E, et al. Sensorimotor integration in focal task-specific hand dystonia: a magnetoencephalographic assessment. *Neuroscience* 2008;154:563–571. doi: 10.1016/j.neuroscience.2008.03.045
13. Hirata Y, Matthias S, Eckart A, Thomas E, Christo P. Sensory mapping of lip representation in brass musicians with embouchure dystonia. *Neuroreport* 2004;15:815–818. doi: 10.1097/00001756-200404090-00015
14. Attal Y, Bhattacharjee M, Yelnik J, Cottureau B, Lefevre J, Okada Y, et al. Modeling and detecting deep brain activity with MEG & EEG. *Conf Proc IEEE Eng Med Biol Soc* 2007;2007:4937–4940. doi: 10.1109/IEMBS.2007.4353448