

# Measurement of choroidal perfusion and thickness following systemic sildenafil (Viagra<sup>®</sup>)

David Y. Kim,<sup>1</sup> Ronald H. Silverman,<sup>2,3</sup> Robison Vernon Paul Chan,<sup>1</sup> Aziz A. Khanifar,<sup>1</sup> Mark Rondeau,<sup>3</sup> Harriet Lloyd,<sup>2</sup> Peter Schlegel<sup>4</sup> and Donald Jackson Coleman<sup>2</sup>

<sup>1</sup>Department of Ophthalmology, Weill Cornell Medical College, New York City, New York, USA

<sup>2</sup>Department of Ophthalmology, Columbia University Medical Center, New York City, New York, USA

<sup>3</sup>F.L. Luzzi Center for Biomedical Engineering, Riverside Research Group, New York City, New York, USA

<sup>4</sup>Department of Urology, Weill Cornell Medical College, New York City, New York, USA

## ABSTRACT.

**Purpose:** To demonstrate anatomic and physiologic changes in the human choroid following systemic sildenafil citrate (Viagra<sup>®</sup>) using enhanced depth imaging spectral domain-optical coherence tomography (EDI-OCT) and swept-scan high-frequency digital ultrasound.

**Methods:** Seven healthy male subjects (mean age 32.7 years) were evaluated at baseline and 2 hr after ingesting 50 mg of sildenafil. Swept-scan high-frequency digital ultrasound and EDI-OCT were utilized to measure choroidal perfusion and thickness, respectively. Results were read by masked observers. The Wilcoxon signed-rank test and *t*-test were used to analyse differences in choroidal flow and thickness at baseline and 2 hr after ingestion of sildenafil.

**Results:** Two hours following sildenafil, increased choroidal perfusion was observed in 11 of 12 eyes measured by swept-scan high-frequency digital ultrasound. The mean increase was 3.46 ( $\pm 2.00$ ) times baseline with a range of 0.47–7.80 times baseline ( $p = 0.004$ ). Increased choroidal thickness was observed in 12 of 12 eyes measured with EDI-OCT. The average choroidal thickness increased by 11.6% temporal to the fovea, 9.3% nasal to the fovea and 10.7% underneath the fovea ( $p < 0.001$  for all values).

**Conclusions:** Choroidal perfusion and thickness both increase in response to systemic sildenafil. These changes could secondarily affect retinal function, explain previously reported clinical symptoms and potentially be a useful adjunct for treatment of ocular diseases that would benefit from increased choroidal blood flow.

**Key words:** age-related macular degeneration – blood flow/drug effects – choroid/blood supply – enhanced depth imaging ocular coherence tomography – sildenafil – swept-scan ultrasound – vasodilator agents/pharmacology – vision, ocular/drug effects

Acta Ophthalmol.

© 2012 The Authors

Acta Ophthalmologica © 2012 Acta Ophthalmologica Scandinavica Foundation

doi: 10.1111/j.1755-3768.2011.02305.x

## Introduction

As sildenafil citrate (Viagra<sup>®</sup>, Pfizer, New York, NY, USA) was approved to treat erectile dysfunction (ED), it has become one of the most popular drugs worldwide. It improves erectile function in men with ED by selectively inhibiting cyclic guanosine monophosphate (cGMP)-specific phosphodiesterase type 5 (PDE-5), which is present in all vascular tissues and enhances the smooth muscle relaxant effects of nitric oxide (Ballard et al. 1998; Moreland et al. 1998; CDER 1998).

As early as 2000, a letter to the *NEJM* (Sponsel et al. 2000) proposed that sildenafil may benefit patients with age-related macular degeneration (AMD), but this idea was not developed. Choroidal perfusion has since been reported to be decreased in AMD (Boltz et al. 2010). Other conditions such as pulmonary hypertension and cardiac ischaemia have been found to be favourably treated with sildenafil (Vlachopoulos et al. 2009). This current study of changes in choroidal perfusion was instituted to demonstrate a means of measuring the effects of sildenafil for possible use in treating conditions related to choroidal ischaemia, such as AMD.

The choroid, which supports the metabolic function of the outer retina, has been described as an erectile tissue, analogous in many respects to the corpus cavernosum (Duke-Elder & Wybar 1961). The fenestrated choroidal vasculature is highly responsive to both local and neurogenic stimuli, and the uveal system may hold up to 97% of the intraocular blood volume (Paris et al. 2001). An increase in choroidal blood flow could secondarily affect retinal and retinal pigment epithelial function and could predispose users to serous retinal detachment or retinal oedema. Conversely, there is potential for sildenafil, or similar pharmacologic agents, to be useful adjuncts for treatment of ocular diseases, which would benefit from increased blood flow in the eye. A reliable method of measuring blood flow in the choroid may shed light on these issues.

Several studies have looked at the effect of sildenafil on ocular blood flow. Sildenafil appears to increase blood flow velocity significantly in the retrobulbar circulation, and most studies suggest an increase in choroidal blood flow with a lesser effect on the retinal vasculature (Harris et al. 2008). However, reported effects of sildenafil on ocular circulation have been inconsistent. Measurements of choroidal thickness using conventional ultrasonography found a small inconsistent change after sildenafil (McCulley et al. 2002). Vance et al. (2011) recently demonstrated an increase in choroidal thickness after sildenafil, but choroidal perfusion was not measured. This may reflect the difficulty in measuring relatively small changes in the choroidal vasculature by most available methods. We present a system that has allowed us to accurately make both perfusion and thickness measurements of the choroid by using sophisticated ultrasonic and optical coherence tomography techniques.

## Methods

This study was performed under a protocol approved by the Institutional Review Board of Weill Medical College of Cornell University and adhered to the tenets of the Declaration of Helsinki. Informed consent was obtained in writing from all subjects.

Seven male subjects (mean age 32.7 years, range 30–38 years) were

evaluated using swept-scan high-frequency digital ultrasound and enhanced depth imaging spectral domain–optical coherence tomography (EDI-OCT). Ultrasound was performed on both eyes of five subjects and only the right eye of two subjects. Enhanced depth imaging spectral domain–optical coherence tomography was performed on both eyes of six subjects. One subject underwent ultrasound but not EDI-OCT. Measurements were obtained at baseline and 2 hr after 50 mg of systemic sildenafil citrate (Pfizer). Subjects were instructed to refrain from eating for at least 4 hr prior to the study.

The swept-mode ultrasound technique we employed is a modification of the standard B-mode acquisition process that allows time–domain (as opposed to Doppler) assessment of flow by speckle tracking, as previously described (Kruse et al. 1998; Silverman et al. 1999). Speckle tracking is advantageous in maintaining high spatial resolution in comparison to colour-flow Doppler.

Scans were performed using a prototype ultrasound instrument of our own design. The system utilized a focused single-element 20 MHz transducer providing  $75 \times 225 \mu\text{m}$  axial-by-lateral resolution with an imaging depth of over 3 mm, thus, providing superior detail of retinal and choroidal structures compared with conventional 10-MHz systems.

Examinations were performed using an immersion technique with the subject in a supine position. After establishing topical anaesthesia with two drops of proparacaine HCl, a Barraquer speculum was inserted to hold the lids open. With a steridrape supported by a ringstand forming a watertight seal about the eye, warm normal saline solution was used to establish a fluid standoff medium between the transducer and the eye. Range was adjusted to place the transducer focal zone on the retina, and the transducer was moved in an arc such that the focus approximately followed the retinal curvature. Each scan consisted of 1024 vectors (lines-of-sight) spaced at  $5\text{-}\mu\text{m}$  increments at a rate of 500 vectors/second. Echo data were digitized at 250 MHz (8-bit resolution).

In swept-scan mode, successive vectors are placed at intervals much smaller

than a beam width. Such vectors are not independent spatially and are effectively looking in one direction over time. This allows particle motion (i.e. flowing blood cells) to be visualized by detecting local axial shifts in echo data along successive vectors, as they are effectively looking at one spatial region over time. A conventional B-scan image is formed from more widely spaced, independent vectors. Because of the relatively slow pulse repetition frequency of the system (500 Hz), aliasing (i.e. particles moving too fast to be tracked by successive vectors) prevented accurate measurement of particle velocity, but did allow visualization of perfused tissue regions. We therefore measured the fractional area of the choroid with detectable perfusion rather than particle velocity or volumetric flow. As each scan plane consisted of 1024 vectors, data were acquired over a period of two seconds. Thus, while flow information along each vector is instantaneous, and thus dependent upon the relationship to the phase of the cardiac cycle (to the extent that this affects choroidal flow), the overall information effectively averages out this effect because of the long duration of data acquisition. To quantify perfusion, a masked observer quantified the number of pixels demonstrating detectable choroidal perfusion for each scan, averaging the results of six scans from each eye. The ratio of post- versus presildenafil perfused choroidal area was determined. A one-sample *t*-test was performed, testing the hypothesis that their ratio was unity. Also, a non-parametric Wilcoxon signed-rank test was performed. In each case, statistics were computed for the aggregate twelve eyes, and separately for the seven right and five left eyes.

Enhanced depth imaging spectral domain–optical coherence tomography imaging was performed using a method described previously (Spaide et al. 2008). Briefly, the choroid was imaged by positioning the Heidelberg Spectralis<sup>®</sup> (Heidelberg Engineering, Heidelberg, Germany) to obtain an inverted image of the posterior pole. A 30-degree horizontal section was obtained, comprising 100 averaged scans, going directly through the foveal centre and encompassing the macula and optic nerve. The Heidelberg Eye Explorer software [version

1.5.12.0; Heidelberg Engineering GmbH (Carlsbad, CA, USA)] was used to measure choroidal thickness from the outer border of the retinal pigment epithelium to the inner scleral border by a masked observer. Thickness measurements were obtained directly at the fovea and at 500- $\mu\text{m}$  intervals from the fovea out to 3 mm in the nasal and temporal directions. The paired *t*-test was used to analyse differences in choroidal thickness at baseline and two hours after ingestion of sildenafil.

## Results

Following systemic sildenafil citrate, 11 of 12 eyes demonstrated increased choroidal perfusion measured by swept-scan ultrasound. This was statistically significant on the Wilcoxon signed-rank test ( $Z = -2.18$ ,  $p = 0.034$ ) when considering all twelve eyes. Six of seven right eyes showed increased perfusion, but this was not sufficient to reach statistical significance. All five left eyes showed increased perfusion, and this was statistically significant ( $Z = -2.02$ ,  $p = 0.043$ ). The ratio of post-treatment/baseline choroidal perfusion values ranged from 0.47 to 7.80 and averaged  $3.46 (\pm 2.00)$ . This was statistically significant by the one-sample *t*-test ( $t = 3.66$ ,  $p = 0.004$ , Figs 1 and 2). In the seven right eyes, the average post-treatment/baseline cho-

roidal perfusion ratio was  $3.00 (\pm 2.50)$ , but this was only of borderline significance ( $t = 2.12$ ,  $p = 0.078$ ). In the five left eyes, the average post-treatment/baseline choroidal perfusion ratio was  $3.50 (\pm 1.57)$ , which was statistically significant ( $t = 3.56$ ,  $p = 0.024$ ).

Choroidal thickness measured with EDI-OCT was increased for 12 of 12 eyes (Figs 3 and 4). In right eyes, the average baseline choroidal thickness was  $291 \mu\text{m}$  temporal to the fovea,  $226 \mu\text{m}$  nasal to the fovea and  $294 \mu\text{m}$  underneath the fovea. The average choroidal thickness in right eyes increased by 11.7% to  $325 \mu\text{m}$  temporal to the fovea (Avg =  $34.0 \mu\text{m}$ , SD =  $16.9 \mu\text{m}$ ), 7.5% to  $243 \mu\text{m}$  nasal to the fovea (Avg =  $17.0 \mu\text{m}$ , SD =  $14.7 \mu\text{m}$ ) and 11.2% to  $327 \mu\text{m}$  underneath the fovea (Avg =  $32.8 \mu\text{m}$ , SD =  $8.3 \mu\text{m}$ ;  $p < 0.001$  for all values). In left eyes, the average baseline choroidal thickness was  $308 \mu\text{m}$  temporal to the fovea,  $239 \mu\text{m}$  nasal to the fovea and  $316 \mu\text{m}$  underneath the fovea. The average choroidal thickness in left eyes increased by 11.5% to  $343 \mu\text{m}$  temporal to the fovea (Avg =  $35.4 \mu\text{m}$ , SD =  $18.3 \mu\text{m}$ ), 11.0% to  $265 \mu\text{m}$  nasal to the fovea (Avg =  $26.3 \mu\text{m}$ , SD =  $18.8 \mu\text{m}$ ) and 10.2% to  $348 \mu\text{m}$  underneath the fovea (Avg =  $32.2 \mu\text{m}$ , SD =  $19.5 \mu\text{m}$ ;  $p < 0.001$  for all values). For all eyes combined, the average baseline choroidal thickness was

$299 \mu\text{m}$  temporal to the fovea,  $232 \mu\text{m}$  nasal to the fovea and  $305 \mu\text{m}$  underneath the fovea. The average choroidal thickness for all eyes increased by 11.6% to  $334 \mu\text{m}$  temporal to the fovea (Avg =  $34.7 \mu\text{m}$ , SD =  $14.6 \mu\text{m}$ ), 9.3% to  $254 \mu\text{m}$  nasal to the fovea (Avg =  $21.6 \mu\text{m}$ , SD =  $16.1 \mu\text{m}$ ) and 10.7% to  $337 \mu\text{m}$  underneath the fovea (Avg =  $32.5 \mu\text{m}$ , SD =  $11.2 \mu\text{m}$ ;  $p < 0.001$  for all values).

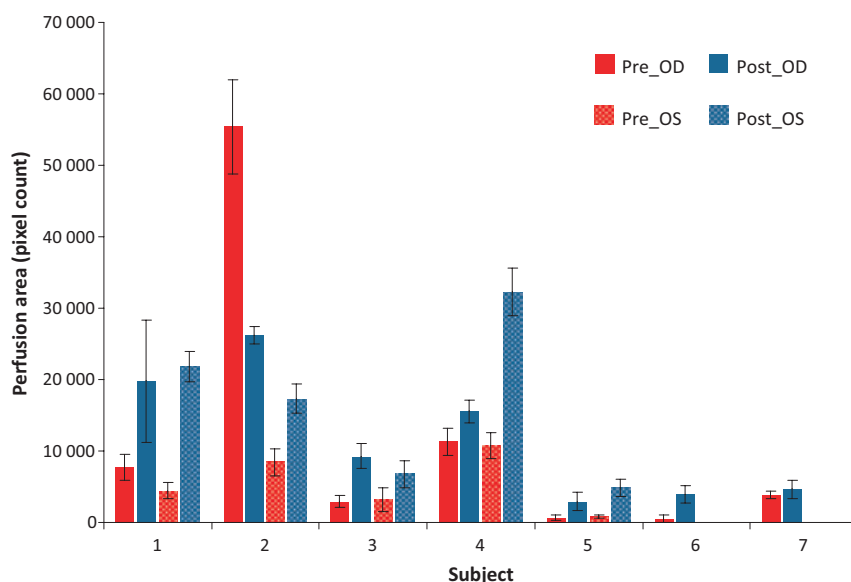
No serious side effects were noted. Three of the seven subjects noted a mild headache and one subject noted facial flushing, all of which resolved spontaneously.

## Discussion

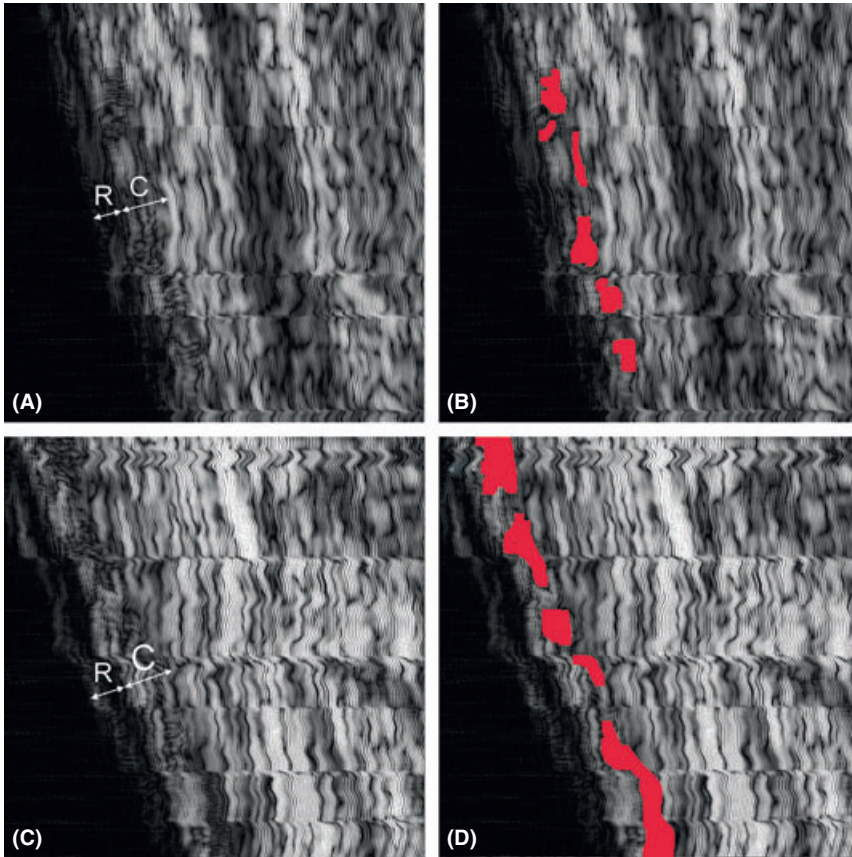
The limited ability to measure choroidal perfusion and thickness variations in the living state has prevented satisfactory documentation of its function, while it is blood-filled and physiologically active. We present a system that has allowed us to make accurate measurements of the choroid by using sophisticated ultrasonic and optical coherence techniques. We demonstrate increased choroidal perfusion and thickness after ingestion of systemic sildenafil citrate. There was a statistically significant increase in choroidal perfusion as measured by 20-MHz swept-scan ultrasound, as well as a statistically significant increase in choroidal thickness as measured by EDI-OCT 2 hr after 50 mg of sildenafil.

All eyes in our study demonstrated a significant increase in choroidal thickness and all eyes, but one, demonstrated an increase in choroidal perfusion after sildenafil. This one subject had what appeared to be a clearly spurious presildenafil baseline choroidal perfusion measurement. However, the spurious measurement may have an anatomical basis. Delay (personal communication) described an anatomical shunt vessel in the area of our measurement, and we may have recorded one of these high-flow vessels. This subject did not have any observable abnormalities on binocular ophthalmoscopy.

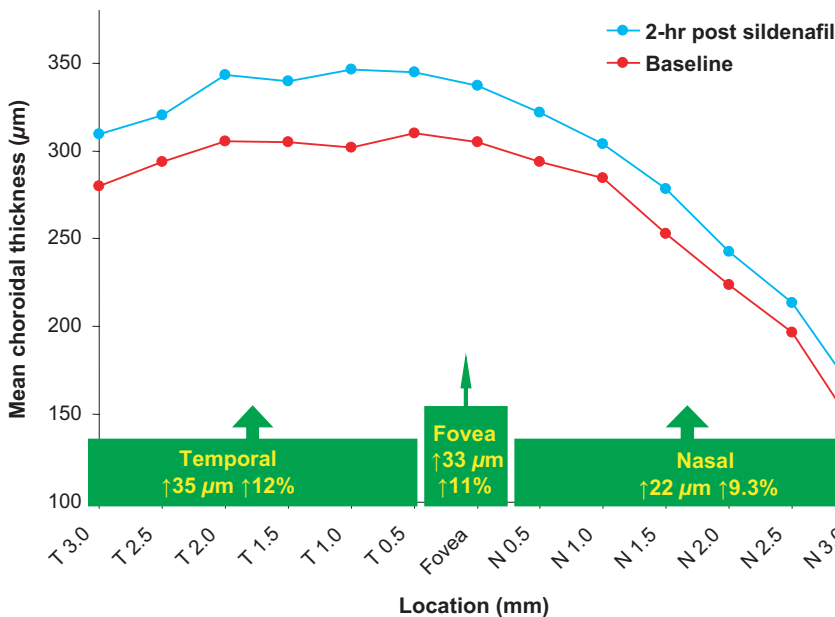
A previous study (Paris et al. 2001) used pulsatile ocular blood flow (POBF) to demonstrate an increase in non-retinal blood flow (+29.4%,  $p = 0.016$ ) 2 hr after 50 mg of sildenafil. However, POBF is an indirect measure of choroidal flow and actually



**Fig. 1.** Choroidal flow at baseline and 2 hr after 50 mg of sildenafil citrate measured by swept-scan high-frequency digital ultrasound. The average perfusion ratio was 3.21 times baseline perfusion. The perfusion ratio ranged from 0.47 to 7.80 times baseline perfusion ( $p = 0.004$ ).



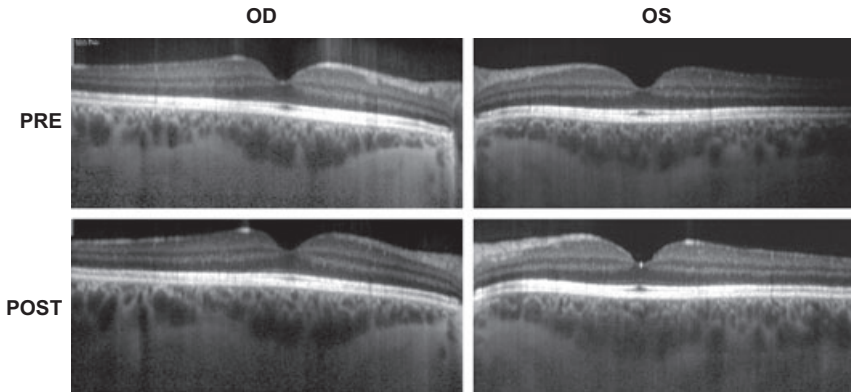
**Fig. 2.** Example of a subject demonstrating increased choroidal flow after 50 mg of sildenafil citrate measured by swept-mode ultrasound. (A) Baseline swept-mode image, indicating retina (R) and choroid (C). (B) Pretreatment swept-mode image with regions of choroidal perfusion indicated in red. (C) Swept-mode image 2 hr after sildenafil citrate. (D) Post-treatment swept-mode image with regions of choroidal perfusion indicated in red. For this eye, the mean perfusion ratio (post/pre) was 3.01. Images are 3.1 mm in depth.



**Fig. 3.** Average choroidal thickness at baseline and 2 hr after 50 mg of sildenafil citrate measured by enhanced depth imaging optical coherence tomography. The average choroidal thickness for all eyes increased by 11.6% to 334 µm temporal to the fovea, 9.3% to 254 µm nasal to the fovea and 10.7% to 337 µm directly underneath the fovea ( $p < 0.001$ ).

measures general ocular hemodynamics, of which the choroid comprises a portion. Laser Doppler flowmetry (LDF) was used to measure choroidal flow in the foveal avascular zone 1 and 5 hr after 100 mg of sildenafil (Grunwald et al. 2001). They did not detect any change in flow underneath the fovea. However, LDF is limited in scope and may not take into account regional differences in choroidal flow. Colour Doppler imaging (CDI) showed an increase in flow in the ophthalmic artery, but failed to show an increase in flow in the central retinal artery or temporal short posterior ciliary artery (SPCA), which feed the subfoveal choroid, after 50 mg of sildenafil (Dündar et al. 2001). Of note, it is technically difficult to locate and assess the SPCA using CDI. The Retinal Vessel Analyser (RVA, Carl Zeiss Meditech, Dublin, CA, USA) showed an increase in retinal arterial and venous diameters after 50 mg of sildenafil, suggesting an increase in retinal blood flow (Pache et al. 2002). These results were in conflict with those of the previously noted study by Paris et al. (2001). Histological sections from rats fed with sildenafil for 4 weeks found an increase in mean choroidal capillary diameter ( $3.44 \pm 1.68\text{-}\mu\text{m}$  versus the control of  $1.78 \pm 1.36\text{-}\mu\text{m}$ ,  $p < 0.001$ ) (Vatansever et al. 2003). A review by Harris et al. (2008) summarizes these and other studies looking at the effect of sildenafil on ocular blood flow using a variety of techniques, which have shown inconsistent results because of the technical difficulty of directly measuring choroidal flow. The method used in the current study offers significant advantages over current semi-quantitative methods, including laser and colour Doppler technology, by providing truly quantitative localized measurements of perfusion in the choroid.

The vascular coat of the eye has long been considered responsible for numerous effects on ocular physiologic processes. At least three physiologic functions of the choroid have been described: nutrition, pressure regulation and dissipation of radiant energy. A study of blood flow in albino rabbits revealed a steady and highly linear flow velocity, suggesting the importance of the choroid in supplying physiologic support for the retina, as well as the ominous retinal consequences of its interruption (Fried-



**Fig. 4.** Example of a subject demonstrating increased choroidal flow after 50 mg of sildenafil citrate measured by enhanced depth imaging optical coherence tomography. The choroidal thickness increased by an average of 40  $\mu\text{m}$  or 16% from baseline in the right eye and 63  $\mu\text{m}$  or 23% in the left eye.

man & Oak 1965). The importance of the choroid was perhaps only mildly overestimated by Magitot (Wudka & Leopold 1956), who believed that 'more than half of ocular pathology is a consequence of disturbances that develop in the layers of the choroid.'

The increase in perfusion after sildenafil, as demonstrated in our study, could be clinically relevant in a number of ocular diseases, including non-arteritic anterior ischaemic optic neuropathy (NAION), glaucoma, central serous chorioretinopathy (CSCR), degenerative myopia and AMD. NAION is thought to be because of decreased perfusion within the paraoptic posterior ciliary arteries that supply the optic nerve head, but the specific mechanism remains unproven (Arnold 2001). Hayreh (1996) described a 'watershed zone' of the posterior ciliary arteries between the choroid and optic nerve. A change in ocular haemodynamics may create an optic nerve 'steal syndrome' with blood flow preferentially channelled to the choroid instead of the optic nerve and may be a possible cause of the reported association of NAION with sildenafil. Glaucoma patients with peripapillary atrophy of choroidal vessels are at increased risk for glaucoma progression (Teng et al. 2010). Decreased choroidal blood flow could plausibly be involved. Cases of CSCR have been reported in patients using PDE-5 inhibitors (Allibhai et al. 2004; Quiram et al. 2005; Fraunfelder & Fraunfelder 2008). Central serous chorioretinopathy is characterized by a serous elevation of the neurosensory retina, and it is plausible that an increase in chori-

dal flow may incite or exacerbate this condition. Patients with degenerative myopia were found to have increased choroidal thinning related to the degree of myopia (Fujiwara et al. 2009). An associated decrease in flow may contribute to retinal atrophy.

The choroid also plays an important role in the pathogenesis of AMD, in addition to the retinal pigment epithelium (RPE) and Bruch's membrane (Zarbin 2004). Several investigators have reported significant vascular alterations of the choroid in both ageing and AMD, such as changes in choriocapillaris density and volume, as well as choroidal vessel diameter (Ramratnan et al. 1994; Spraul et al. 1996). A non-specific PDE inhibitor, moxaverine, delivered intravenously increased choroidal flow in patients with AMD (Pemp et al. 2010). In contrast, sildenafil failed to increase choroidal flow in patients with AMD (Metelitsina et al. 2005). However, measurements in that study were made using laser Doppler flowmetry and only in the centre of the foveola. In another study using ultrasonography (Koksal et al. 2005), central retinal artery velocities were not changed, but ophthalmic artery and SPCA velocities were significantly increased after sildenafil, supporting our findings of increased choroidal perfusion after sildenafil.

Hayreh first described 'watershed zones' in the choroid using fluorescein angiography (Hayreh 1974). In the case of generalized chronic vascular insufficiency or diffuse microvascular insult, these zones could be vulnerable to ischaemia, especially in the highly

metabolically active macula, where numerous watershed zones of the SPCA are found (Hayreh 1990). Age-related macular degeneration-associated choriocapillaris dysfunction could exacerbate these potentially ischaemic watershed zones resulting in ischaemia predisposing to choroidal neovascularization or geographic atrophy (Ross et al. 1998). Ischaemia of the choroid has been implicated in several studies of AMD. Increasing choroidal flow in decreased flow states may be a therapeutic target for agents that increase choroidal blood flow.

In other work in our laboratory, we demonstrated high-resolution choroidal imaging with a technique called wavelet analysis, which provides capability for boundary analysis of the choroidal and retinal interface to examine disease-dependent variations in the microvasculature (Coleman et al. 2005a; Coleman et al. 2005b). This provides additional information for examining the natural history and for monitoring treatment of choroidal pathology, such as in AMD. Perfusion studies using swept-scan and wavelet ultrasound techniques may be the ideal way of gauging dosage and timing of sildenafil and similar agents in studying choroidal ischaemia in AMD.

Our study is limited by the small sample size and in that all our patients were healthy young men. In addition, our study was not designed to assess the complete time course of the effect of sildenafil on choroidal blood flow.

In summary, we have found increased choroidal perfusion and thickness after use of systemic sildenafil citrate. There was a statistically significant increase in choroidal perfusion as measured by swept-scan ultrasound, as well as a statistically significant increase in choroidal thickness as measured by EDI-OCT after 50 mg of sildenafil. These changes could secondarily affect retinal function and explain previously reported clinical symptoms and may also be a potentially useful adjunct for treatment of ocular diseases that would benefit from increased choroidal blood flow.

## Acknowledgements

The authors have no proprietary interest in any aspect of this report. A

portion of this work was supported by NIH EB000238, the Dyson Foundation, the St. Giles Foundation and Research to Prevent Blindness.

## References

- Allibhai ZA, Gale JS & Sheidow TS (2004): Central serous chorioretinopathy in a patient taking sildenafil citrate. *Ophthalmic Surg Lasers Imaging* **35**: 165–167.
- Arnold AC (2003): Pathogenesis of nonarteritic anterior ischemic optic neuropathy. *J Neuroophthalmol* **23**: 157–63.
- Ballard SA, Gingell CJ, Tang K, Turner LA, Price ME & Naylor AM (1998): Effects of sildenafil on the relaxation of human corpus cavernosum tissue in vitro and on the activities of cyclic nucleotide phosphodiesterase isozymes. *J Urol* **159**: 2164–2171.
- Boltz A, Luksch A, Wimpfissinger B et al. (2010): Choroidal blood flow and progression of age-related macular degeneration in the fellow eye in patients with unilateral choroidal neovascularization. *Invest Ophthalmol Vis Sci* **51**: 4220–4225.
- Center for Drug Evaluation and Research (1998): Phase I investigator-blind, placebo controlled, evaluation of safety, toleration, and pharmacokinetics of sildenafil following escalating single oral doses in healthy male volunteers: study 148-004. In: *Viagra (Sildenafil): Joint Clinical Review for NDA-20-895*. Washington, DC: Center for Drug Evaluation and Research, Food and Drug Administration.
- Coleman DJ, Silverman RH, Lizzi FL, Rondeau MJ, Lloyd HO, Daly SW & Reinstein DZ (2005a): Ultrasonography of the eye and orbit, 2nd Edn. Philadelphia: Lippincott Williams & Wilkins.
- Coleman DJ, Rondeau MJ, Silverman RH, Lloyd HO & Lizzi FL (2005b): High-resolution ultrasound spectral and wavelet analysis of the choroid in AMD. *Invest Ophthalmol Vis Sci* **46**: 2432.
- Duke-Elder S & Wybar K (1961): Anatomy of the visual systems. In: *Duke-Elder S (ed.). System of ophthalmology, vol 2*. St. Louis: CV Mosby Co. 132.
- Dündar SO, Dündar M, Koçak I, Dayanir Y & Ozkan SB (2001): Effect of sildenafil on ocular haemodynamics. *Eye* **15**: 507–510.
- Fraunfelder FW & Fraunfelder FT (2008): Central serous chorioretinopathy associated with sildenafil. *Retina* **28**: 606–609.
- Friedman E & Oak SM (1965): Choroidal microcirculation in vivo. *Bibl Anat* **7**: 129–132.
- Fujiwara T, Imamura Y, Margolis R, Slakter JS & Spaide RF (2009): Enhanced depth imaging optical coherence tomography of the choroid in highly myopic eyes. *Am J Ophthalmol* **148**: 445–450. [Epub 2009 Jul 9].
- Grunwald JE, Siu KK, Jacob SS & Dupont J (2001): Effect of sildenafil citrate (Viagra) on the ocular circulation. *Am J Ophthalmol* **131**: 751–755.
- Harris A, Kagemann L, Ehrlich R, Ehrlich Y, López CR & Purvin VA (2008): The effect of sildenafil on ocular blood flow. *Br J Ophthalmol* **92**: 469–473.
- Hayreh SS (1974): Submacular choroidal vascular pattern. Experimental fluorescein fundus angiographic studies. *Albrecht Von Graefes Arch Klin Exp Ophthalmol* **192**: 181–196.
- Hayreh SS (1990): In vivo choroidal circulation and its watershed zones. *Eye (Lond)* **4**(Pt 2): 273–289.
- Hayreh SS (1996): Acute ischemic disorders of the optic nerve: pathogenesis, clinical manifestations and management. *Ophthalmol Clin North Am* **9**: 407–442.
- Koksal M, Ozdemir H, Kargi S, Yesilli C, Tomaç S, Mahmutyazicioglu K & Mungan A (2005): The effects of sildenafil on ocular blood flow. *Acta Ophthalmol Scand* **83**: 355–359.
- Kruse DE, Silverman RH, Fornaris RJ, Coleman DJ & Ferrara KW (1998): A swept-scanning mode for estimation of blood velocity in the microvasculature. *IEEE Trans Ultrason Ferroelectr Freq Control* **45**: 1437–1440.
- McCulley TJ, Luu JK, Marmor MF & Feuer WJ (2002): Effects of sildenafil citrate (Viagra) on choroidal congestion. *Ophthalmologica* **216**: 455–458.
- Metelitsina TI, Grunwald JE, DuPont JC & Ying GS (2005): Effect of Viagra on the foveolar choroidal circulation of AMD patients. *Exp Eye Res* **81**: 159–164.
- Moreland RB, Goldstein I & Traish A (1998): Sildenafil, a novel inhibitor of phosphodiesterase type 5 in human corpus cavernosum smooth muscle cells. *Life Sci* **62**: 309–318.
- Pache M, Meyer P, Prünke C, Orgül S, Nuttli I & Flammer J (2002): Sildenafil induces retinal vasodilatation in healthy subjects. *Br J Ophthalmol* **86**: 156–158.
- Paris G, Sponsel WE, Sandoval SS, Elliott WR, Trigo Y, Sanford DK & Harrison JM (2001): Sildenafil increases ocular perfusion. *Int Ophthalmol* **23**: 355–358.
- Pemp B, Garhofer G, Lasta M, Schmidl D, Wolzt M & Schmetterer L (2010): The effects of moxaverine on ocular blood flow in patients with age-related macular degeneration or primary open angle glaucoma and in healthy control subjects. *Acta Ophthalmol* **90**: 139–145.
- Quiram P, Dumars S, Parwar B & Sarraf D (2005): Viagra-associated serous macular detachment. *Graefes Arch Clin Exp Ophthalmol* **243**: 339–344.
- Ramrattan RS, van der Schaft TL, Mooy CM, de Bruijn WC, Mulder PG & de Jong PT (1994): Morphometric analysis of Bruch's membrane, the choriocapillaris, and the choroid in aging. *Invest Ophthalmol Vis Sci* **35**: 2857–2864.
- Ross RD, Barofsky JM, Cohen G, Baber WB, Palao SW & Gitter KA (1998): Presumed macular choroidal watershed vascular filling, choroidal neovascularization, and systemic vascular disease in patients with age-related macular degeneration. *Am J Ophthalmol* **125**: 71–80.
- Silverman RH, Kruse DE, Coleman DJ & Ferrara KW (1999): High-resolution ultrasonic imaging of blood flow in the anterior segment of the eye. *Invest Ophthalmol Vis Sci* **40**: 1373–1381.
- Spaide RF, Koizumi H & Pozzoni MC (2008): Enhanced depth imaging spectral-domain optical coherence tomography. *Am J Ophthalmol* **146**: 496–500.
- Sponsel WE, Paris G, Sandoval SS, Sanford DK, Harrison JM, Elliott WR & Trigo Y (2000): Sildenafil and ocular perfusion. *N Engl J Med* **342**: 1680.
- Spraul CW, Lang GE & Grossniklaus HE (1996): Morphometric analysis of the choroid, Bruch's membrane, and retinal pigment epithelium in eyes with age-related macular degeneration. *Invest Ophthalmol Vis Sci* **37**: 2724–2735.
- Teng CC, De Moraes CG, Prata TS, Tello C, Ritch R & Liebmann JM (2010): Beta-Zone parapapillary atrophy and the velocity of glaucoma progression. *Ophthalmology* **117**: 909–915. [Epub 2010 Feb 4].
- Vance SK, Imamura Y & Freund KB (2011): The effects of sildenafil citrate on choroidal thickness as determined by enhanced depth imaging optical coherence tomography. *Retina* **31**: 332–335.
- Vatansever HS, Kayikcioglu O & Gumus B (2003): Histopathologic effect of chronic use of sildenafil citrate on the choroid & retina in male rats. *Indian J Med Res* **117**: 211–215.
- Vlachopoulos C, Terentes-Printzios D, Ioakeimidis N, Rokkas K & Stefanadis C (2009): PDE5 inhibitors in non-urological conditions. *Curr Pharm Des* **15**: 3521–3539.
- Wudka E & Leopold IH (1956): Experimental studies of the choroidal vessels I. Historical survey. II. Methods and material of investigation. III. Anatomical observations. *AMA Arch Ophthalmol* **55**: 605–632.
- Zarbin MA (2004): Current concepts in the pathogenesis of age-related macular degeneration. *Arch Ophthalmol* **122**: 598–614.

Received on March 22nd, 2011.

Accepted on September 17th, 2011.

### Correspondence:

Donald Jackson Coleman, MD  
 Department of Ophthalmology  
 Columbia University Medical Center  
 635 West 165th Street, Rm 532  
 New York, NY 10032  
 USA  
 Tel: + 212-302-2703  
 Fax: + 646-426-0202  
 Email: dr2626@columbia.edu