



Published in final edited form as:

Mov Disord. 2009 August 15; 24(11): 1600–1605. doi:10.1002/mds.22567.

Torpedoes in Parkinson's Disease, Alzheimer's Disease, Essential Tremor, and Control Brains

Elan D. Louis, MD, MSc^{1,2,3,5}, Phyllis L. Faust, MD, PhD⁴, Jean-Paul G. Vonsattel, MD^{3,4}, Lawrence S. Honig, MD, PhD^{1,2,3}, Alex Rajput, MD⁶, Ali Rajput, MD⁶, Rajesh Pahwa, MD⁷, Kelly E Lyons, PhD⁷, G. Webster Ross, MD^{8,9,10,11}, Rodger J. Elble, MD, PhD¹², Cordelia Erickson-Davis, BA¹, Carol B. Moskowitz, MS^{1,2}, and Arlene Lawton, RN^{1,3}

¹ GH Sergievsky Center, Columbia University, New York, NY, USA

² Department of Neurology, Columbia University, New York, NY, USA

³ Taub Institute for Research on Alzheimer's Disease and the Aging Brain, Columbia University, New York, NY, USA

⁴ Department of Pathology and Cell Biology, College of Physicians and Surgeons, Columbia University, New York, NY, USA

⁵ Department of Epidemiology, Mailman School of Public Health, Columbia University, New York, NY, USA

⁶ Royal University Hospital, Saskatoon, Saskatchewan, Canada

⁷ Department of Neurology, University of Kansas Medical Center, Kansas City, KS, USA

⁸ Veterans Affairs Pacific Islands Health Care System, University of Hawaii John A. Burns School of Medicine, Honolulu, HI, USA

⁹ Departments of Medicine and Geriatrics, University of Hawaii John A. Burns School of Medicine, Honolulu, HI, USA

¹⁰ Pacific Health Research Institute, Honolulu, HI, USA

¹¹ Kuakini Medical Center/Honolulu-Asia Aging Study, Honolulu, HI, USA

¹² Department of Neurology, Southern Illinois University School of Medicine, Springfield, IL, USA

Abstract

Background—Purkinje cell axonal swellings (“torpedoes”), described in several cerebellar disorders as well as essential tremor (ET), have not been quantified in common neurodegenerative conditions.

Correspondence: Dr. Elan Louis, Unit 198, Neurological Institute, 710 West 168th Street, New York, NY, 10032, USA. Tel: (212) 305 - 9194, FAX: (212) 305 -1304, Email: EDL2@columbia.edu.

Disclosure: The authors report no conflicts of interest.

Statistical Analyses: The statistical analyses were conducted by Dr. Louis.

Author Contributions

Elan D. Louis: Research project conception, organization and execution; statistical analyses design and execution; manuscript writing (writing the first draft and making subsequent revisions).

Phyllis L. Faust, Jean-Paul G. Vonsattel, Lawrence S. Honig, Alex Rajput, Ali Rajput, Rajesh Pahwa, Kelly E Lyons, G. Webster Ross, Rodger J. Elble, Cordelia Erickson-Davis, Carol B. Moskowitz, and Arlene Lawton: Research project execution; manuscript writing (making subsequent revisions).

Objective—To quantify torpedoes Parkinson’s disease (PD) and Alzheimer’s disease (AD) compared with ET and control brains.

Methods—Brains included 40 ET cases (34 cerebellar ET, 6 Lewy body variant of ET) and age-matched comparison brains (21 AD, 14 PD/diffuse Lewy body disease, 25 controls). Torpedoes were counted in 20×25 mm cerebellar cortical sections stained with Luxol Fast Blue/Hematoxylin and Eosin.

Results—The median number of torpedoes in cerebellar ET (12) was 12x higher than that of controls (1) and nearly 2.5x higher than in AD (5) or PD/DLBD (5)(all $p \leq 0.005$). Furthermore, in a logistic regression model that adjusted for age and Alzheimer’s-type changes, each torpedo more than doubled the odds of having cerebellar ET (Odds ratio_{cerebellar ET vs. control} = 2.57, $p = 0.006$), indicating that the association between increased torpedoes and cerebellar ET was independent of these Alzheimer’s-type changes.

Conclusions—While torpedoes are increased in AD and PD, as well as cerebellar ET, the magnitude of increase in cerebellar ET is greater, and cannot be accounted for by concomitant AD or PD pathology.

Keywords

Essential tremor; cerebellum; torpedoes; Parkinson’s disease; pathology; Alzheimer’s disease

Introduction

Torpedoes, swellings of the proximal portion of the Purkinje cell axon, are presumed to represent a cellular response to injury.¹ These lesions have recently been described in patients with essential tremor (ET), where their numbers have been shown to be several-fold higher than seen in similarly-aged control brains.^{2, 3} Torpedoes have been described in several other disorders including cerebellar damage from mercury toxicity, cerebellar ataxias, and paraneoplastic cerebellar ataxia.^{4, 5} More broadly, the question arises as to whether these lesions also occur in patients with common neurodegenerative conditions such as Alzheimer’s disease (AD) and Parkinson’s disease (PD). This is particularly important because each of these diseases, and especially AD, may co-occur in elderly patients with ET, confounding the interpretation of results.^{6, 7} Cerebellar abnormalities have been reported in PD brains (alpha-synuclein inclusions in Purkinje cell axons⁸ and Bergmann glial cells⁹). Various cerebellar abnormalities have also been described in AD, including Purkinje cell loss and gliosis,^{10–12} and lipopigment changes.¹³ However, torpedoes have not been systematically assessed in either of these diseases. Our aim was to quantify the number of torpedoes in postmortem cerebellar tissue in patients with PD and AD, and to compare these to ET and control brains of similar age. The underlying question is how specific these lesions are to ET, a disease whose neuropathological underpinnings are only now beginning to emerge.³

Methods

Tissue was analyzed at the New York Brain Bank, Columbia University Medical Center. The 100 brains included ET (N = 40 [31 reported previously²]), AD (N = 21), PD or diffuse Lewy body disease (DLBD) (N = 14) and controls (N = 25 [21 reported previously²]).

40 ET brains were obtained from the Essential Tremor Centralized Brain Repository (New York Brain Bank).^{2, 14} As documented,² brains were either collected prospectively beginning in 2003 (N = 27) or banked elsewhere and then sent to the New York Brain Bank (N = 13 including the Royal University Hospital in Saskatchewan, Canada; the University of Kansas Brain Bank; the Honolulu-Asia Aging Study; Southern Illinois University Brain Bank; the

Veterans Administration West Los Angeles Healthcare Center; and Sunnybrook Health Sciences Centre, Toronto, Canada). All but one had been diagnosed with ET by their treating neurologist. All diagnoses were confirmed using Essential Tremor Centralized Brain Repository criteria.² One case fulfilled all clinical diagnostic criteria for ET,² despite not having received this diagnosis during life. Two additional ET cases that were included in an earlier series² and who fulfilled pathological criteria for PD, were not included in this series.

AD brains were from individuals who during life had been enrolled as AD cases in the Alzheimer's Disease Research Center or the Washington Heights Inwood Columbia Aging Project, where they were followed prospectively with serial neurological assessments, including assessment of action tremor, and were free of ET or PD. They were 1:2 age-matched to ET brains, yielding 21 AD brains.

PD and DLBD brains at the New York Brain Bank had been patients at the Movement Disorder Division, Neurological Institute of New York or were outside referrals to the brain bank. They were 1:2 age-matched to ET brains, initially yielding 21 brains, but cerebellar tissue sections were unavailable on 7, yielding 14 brains. The final 14 were similar to the excluded 7 in terms of age and gender. These 14 had been diagnosed during life with PD (N = 4), PD with dementia (N = 4), or diffuse Lewy body disease (N = 6).

Control brains were from individuals who had been enrolled as normal elderly control subjects in the Alzheimer's Disease Research Center or the Washington Heights Inwood Columbia Aging Project, where they were followed prospectively with serial neurological assessments, including assessment of action tremor, remaining free of a diagnosis of AD, ET or PD during life, and not having a neuropathological diagnosis after autopsy. Twenty-five brains could be age-matched to cerebellar ET cases.

Demographic and clinical information were collected on each case. All brains underwent complete neuropathological assessment at the New York Brain Bank^{2, 14–17} and were processed according to methods optimizing the yield of fresh frozen samples for research.¹⁸ Brains received ratings of neurofibrillary tangles using Braak & Braak staging^{19, 20} and Consortium to Establish a Registry for Alzheimer's Disease (CERAD) ratings²¹ for neuritic plaques; National Institute on Aging - Reagan Institute (NIA - RI) criteria for AD were assigned.²² Braak PD stage was also assigned.²³ Postmortem interval (PMI) was the number of hours between death and placement of the brain in a cold room or upon ice. The Institutional Review Board of Columbia University Medical Center approved study procedures.

As in previous studies,^{2, 16, 17, 24} a standard 3 × 20 × 25 mm parasagittal tissue block from the neocerebellum (see Figure 5 in¹⁶) was harvested from each brain. Paraffin sections (7 μm thick) were stained with Luxol Fast Blue counterstained with Hematoxylin and Eosin (LH&E) for quantification of torpedoes.^{2, 16, 17} In each brain, torpedoes in one entire LH&E section were counted, blinded to the clinical diagnosis. We have shown that counts on one section correlate robustly with counts on other sections from the same cases (r = 0.86, p < 0.001), indicating that repeat sectioning and counting is likely to yield similar results.

As documented,^{2, 17, 24} ET cases were divided into two groups based on the presence vs. absence of brainstem Lewy bodies on postmortem examination. We have demonstrated that ET brains without Lewy bodies have an emerging array of cerebellar abnormalities that include, but are not limited to, increased numbers of torpedoes. These abnormalities include a reduction in the number of Purkinje cells²⁵ (60% of normal),^{2, 24} swellings of Purkinje cell dendrites,² heterotopic Purkinje cells,² and in some cases, degenerative changes in the dentate nucleus.^{2, 16} Based on this picture, these Lewy body-free brains have been referred to as cerebellar ET in previous publications,³ and we continue that nomenclature here.

Data were analyzed in SPSS (Version 15.0). Number of torpedoes (LH&E) and PMI were not normally distributed. Therefore, non-parametric tests (Spearman's r , Mann-Whitney test) were used for these variables. In logistic regression analyses, diagnosis (cerebellar ET case vs. control) was the dependent variable, and number of torpedoes, the independent variable.

Results

The 100 brains included 40 ET (34 cerebellar ET and 6 LBVET), 21 AD, 14 PD or DLBD, and 25 controls. Cerebellar ET cases and controls did not differ with regards to age; PD/DLBD cases, AD cases and controls were also similar in age (Table 1). AD cases had lower brain weights than controls (Table 1). CERAD plaque score was higher in AD cases than controls, and Braak AD stage was higher in AD cases, cerebellar ET cases and LBVET cases than controls (Table 1). All AD cases met NIA-RI pathological criteria for AD (CERAD plaque score C and Braak stage V or higher); none of the ET cases, PD/DLBD cases or controls met these criteria. Among the 14 PD or DLBD cases, Braak PD stages were V ($N = 3$) and VI ($N = 11$).

The median number of torpedoes in cerebellar ET cases was 12 times higher than that of controls and was significantly higher than that of each of the other groups (Figure 1). It was 2.5 times higher than that of AD ($p = 0.005$) and 2.5 times that of PD/DLBD ($p = 0.002$). The number of torpedoes in AD and PD/DLBD cases was intermediate between that seen in cerebellar ET and controls, and was higher than that seen in controls (Table 1). The number in Lewy body variant of ET did not differ from that of controls (Table 1). After combining all 40 ET brains into one group, the number of torpedoes was 10.5 times higher than seen in controls (median = 10.5, mean = 13.3 ± 12.1 , Mann Whitney $z = 5.17$, $p < 0.001$).

In these 100 brains, there was no association between number of torpedoes and age ($r = 0.15$, $p = 0.14$), brain weight ($r = -0.13$, $p = 0.19$), PMI ($r = 0.09$, $p = 0.46$), Braak AD stage ($r = 0.12$, $p = 0.25$), CERAD plaque score ($r = 0.16$, $p = 0.13$), Braak PD stage ($r = -0.13$, $p = 0.20$) or gender (Mann-Whitney = 1.48, $p = 0.14$). In cerebellar ET cases, number of torpedoes was marginally associated with age of tremor onset ($r = 0.28$, $p = 0.13$) and marginally inversely with tremor duration ($r = -0.35$, $p = 0.06$).

In a logistic regression model that was restricted to cerebellar ET cases and controls, each torpedo nearly doubled the odds of cerebellar ET (odds ratio [OR] = 1.89, 95% confidence interval [CI] = 1.31 – 2.73, $p = 0.001$). The odds remained elevated after adjusting for age, Braak AD stage and CERAD score in a multivariate logistic regression model (OR = 2.57, 95% CI = 1.32 – 5.00, $p = 0.006$), indicating that the association between increased torpedoes and cerebellar ET was *independent* of Alzheimer's-type changes in the brain. To further demonstrate this point, we stratified cerebellar ET cases and controls by CERAD plaque score and Braak AD stage. Within each stratum of Alzheimer's-type change, the number of torpedoes in cerebellar ET was greater than that of controls (i.e., association between increased torpedoes and ET was *independent* of Alzheimer's-type changes in the brain). For example, CERAD plaque score 0 (12.6 ± 13.4 torpedoes in cases vs. 1.9 ± 1.6 torpedoes in controls), CERAD plaque score A (12.0 ± 5.5 vs. 2.0 ± 1.9), CERAD plaque score C (13.7 ± 4.7 vs. 4.0 ± 0.0), and Braak AD stage 0 (15.0 ± 6.6 torpedoes in cases vs. 2.4 ± 1.9 torpedoes in controls), Braak AD stage I (21.0 ± 18.5 vs. 1.4 ± 1.1), Braak AD stage III (10.3 ± 7.5 vs. 0.0 ± 0.0), and Braak AD stage IV (8.4 ± 6.8 vs. 3.0 ± 0.0).

Discussion

This is the first systematic attempt to study these Purkinje cell lesions broadly, not only in ET, but also in other common degenerative diseases. Torpedoes were more abundant in the AD

and PD brain than control brains, indicating that these abnormalities may be found to some extent in these neurodegenerative diseases. Yet this increased number was only a fraction of that seen in cerebellar ET brains. Indeed, the number of torpedoes in cerebellar ET was 2 – 3 times higher than seen in AD and PD, indicating that the magnitude of increase in cerebellar ET is not a feature of these other diseases. Furthermore, in analyses that accounted for Braak AD stage and CERAD score, the association between increased torpedoes and cerebellar ET was *independent* of Alzheimer's-type changes in the brain, indicating that the cerebellar ET vs. control difference is not due to the confounding effects of co-occurring Alzheimer's-type pathologies, which can occur in the ET brain.

Torpedoes are swellings of the proximal portion of the Purkinje cell axon. There is general agreement that they occur in injured Purkinje cells; however, whether they represent a pre-terminal cellular response or a regenerative response is not entirely clear.^{26, 27} Ultrastructurally, torpedoes are comprised of massive accumulations of neurofilaments, which occur in disordered arrangements.^{26–28} In previous analyses, cerebellar ET brains demonstrated an array of cerebellar abnormalities that included torpedoes;³ the diagnostic utility of these abnormalities is currently under investigation.

Recent literature suggests that the odds of ET might be increased in individuals with PD.^{7, 29} Studies also suggest that ET and AD, as two common disorders, can co-occur, and some recent data suggest that there are increased odds and increased risk of AD in individuals with ET above and beyond that expected because of their high prevalences.^{6, 30} This has raised the question as to whether the increased numbers of torpedoes that are seen in ET are due to Alzheimer's-type changes in ET brains; the current data suggest that this is not the case.

This study had limitations. First, the number of ET cases was small. However, this represents the largest assembled collection of ET brains reported in the literature; the current series is approximately double the size of previous series.^{25, 31} In addition, the sample size was adequate for detecting statistically significant differences between cerebellar ET and each of the other diagnostic groups, indicating that the sample size did not limit our ability to detect our main effects. Second, while the cerebellar ET cases and controls did not differ significantly by age, these cases were on average 5.2 years older than controls. However, we showed that number of torpedoes was not correlated with age and, furthermore, the difference between cerebellar ET cases and controls persisted in logistic regression models that adjusted for age. This study also had unique features and strengths. It systematically studied these lesions broadly in ET as well as other common degenerative diseases. Second, we carefully matched diseased cases with similarly-aged control brains. Finally, in each diagnostic group, we documented AD-type pathological changes in order to deal with this important confounding factor.

In summary, torpedoes occur in the AD and PD brain but not to the extent seen in cerebellar ET. Nor do AD-type pathologies account for the abundance of torpedoes in the cerebellar ET brain. Further studies of these lesions will be important to our understanding of the pathogenesis of ET.

Acknowledgments

Funding Source: R01 NS42859, P50 AG08702, and P01 AG07232 from the National Institutes of Health (Bethesda, MD); the Parkinson's Disease Foundation (New York, NY); the Arlene Bronstein Essential Tremor Research Fund (Columbia University); and the Claire O'Neil Essential Tremor Research Fund (Columbia University).

References

1. Kato T, Hirano A. A Golgi study of the proximal portion of the human Purkinje cell axon. *Acta Neuropathol* 1985;68(3):191–195. [PubMed: 3909727]

2. Louis ED, Faust PL, Vonsattel JP, et al. Neuropathological changes in essential tremor: 33 cases compared with 21 controls. *Brain* 2007;130(Pt 12):3297–3307. [PubMed: 18025031]
3. Louis ED, Vonsattel JP. The emerging neuropathology of essential tremor. *Mov Disord* 2007;23(2):174–182. [PubMed: 17999421]
4. Takahashi N, Iwatsubo T, Nakano I, Machinami R. Focal appearance of cerebellar torpedoes associated with discrete lesions in the cerebellar white matter. *Acta Neuropathol* 1992;84(2):153–156. [PubMed: 1523970]
5. Yaginuma M, Ishida K, Uchihara T, et al. Paraneoplastic cerebellar ataxia with mild cerebello-olivary degeneration and an anti-neuronal antibody: a clinicopathological study. *Neuropathol Appl Neurobiol* 2000;26(6):568–571. [PubMed: 11123723]
6. Benito-Leon J, Louis ED, Bermejo-Pareja F. Elderly-onset essential tremor is associated with dementia. *Neurology* 2006;66(10):1500–1505. [PubMed: 16717208]
7. Tan EK, Lee SS, Fook-Chong S, Lum SY. Evidence of increased odds of essential tremor in Parkinson's disease. *Mov Disord* 2008;23(7):993–997. [PubMed: 18383536]
8. Mori F, Piao YS, Hayashi S, et al. Alpha-synuclein accumulates in Purkinje cells in Lewy body disease but not in multiple system atrophy. *J Neuropathol Exp Neurol* 2003;62(8):812–819. [PubMed: 14503637]
9. Piao YS, Mori F, Hayashi S, et al. Alpha-synuclein pathology affecting Bergmann glia of the cerebellum in patients with alpha-synucleinopathies. *Acta Neuropathol* 2003;105(4):403–409. [PubMed: 12624794]
10. Sjobeck M, Englund E. Alzheimer's disease and the cerebellum: a morphologic study on neuronal and glial changes. *Dement Geriatr Cogn Disord* 2001;12(3):211–218. [PubMed: 11244215]
11. Fukutani Y, Cairns NJ, Rossor MN, Lantos PL. Purkinje cell loss and astrocytosis in the cerebellum in familial and sporadic Alzheimer's disease. *Neurosci Lett* 1996;214(1):33–36. [PubMed: 8873125]
12. Wegiel J, Wisniewski HM, Dziewiatkowski J, et al. Cerebellar atrophy in Alzheimer's disease—clinicopathological correlations. *Brain Res* 1999;818(1):41–50. [PubMed: 9914436]
13. Dowson JH, Mountjoy CQ, Cairns MR, Wilton-Cox H, Bondareff W. Lipopigment Changes in Purkinje Cells in Alzheimer's Disease. *J Alzheimers Dis* 1998;1(2):71–79. [PubMed: 12214004]
14. Louis ED, Borden S, Moskowitz CB. Essential tremor centralized brain repository: diagnostic validity and clinical characteristics of a highly selected group of essential tremor cases. *Mov Disord* 2005;20(10):1361–1365. [PubMed: 16001407]
15. Louis ED, Honig LS, Vonsattel JP, Maraganore DM, Borden S, Moskowitz CB. Essential tremor associated with focal nonnigral Lewy bodies: a clinicopathologic study. *Arch Neurol* 2005;62(6):1004–1007. [PubMed: 15956174]
16. Louis ED, Vonsattel JP, Honig LS, et al. Essential tremor associated with pathologic changes in the cerebellum. *Arch Neurol* 2006;63(8):1189–1193. [PubMed: 16908751]
17. Louis ED, Vonsattel JP, Honig LS, Ross GW, Lyons KE, Pahwa R. Neuropathologic findings in essential tremor. *Neurology* 2006;66(11):1756–1759. [PubMed: 16769958]
18. Vonsattel JP, Del Amaya MP, Keller CE. Twenty-first century brain banking. Processing brains for research: the Columbia University methods. *Acta Neuropathol* 2008;115(5):509–532. [PubMed: 17985145]
19. Braak H, Braak E. Diagnostic criteria for neuropathologic assessment of Alzheimer's disease. *Neurobiol Aging* 1997;18(4 Suppl):S85–88. [PubMed: 9330992]
20. Braak H, Alafuzoff I, Arzberger T, Kretschmar H, Del Tredici K. Staging of Alzheimer disease-associated neurofibrillary pathology using paraffin sections and immunocytochemistry. *Acta Neuropathol* 2006;112(4):389–404. [PubMed: 16906426]
21. Mirra SS. The CERAD neuropathology protocol and consensus recommendations for the postmortem diagnosis of Alzheimer's disease: a commentary. *Neurobiol Aging* 1997;18(4 Suppl):S91–94. [PubMed: 9330994]
22. The National Institute on Aging, and Reagan Institute Working Group on diagnostic criteria for the neuropathological assessment of Alzheimer's disease. Consensus recommendations for the postmortem diagnosis of Alzheimer's disease. *Neurobiol Aging* 1997;18(S4):S1–S2. [PubMed: 9330978]

23. Braak H, Del Tredici K, Rub U, de Vos RA, Jansen Steur EN, Braak E. Staging of brain pathology related to sporadic Parkinson's disease. *Neurobiol Aging* 2003;24(2):197–211. [PubMed: 12498954]
24. Axelrad JE, Louis ED, Honig LS, et al. Reduced purkinje cell number in essential tremor: a postmortem study. *Arch Neurol* 2008;65(1):101–107. [PubMed: 18195146]
25. Shill HA, Adler CH, Sabbagh MN, et al. Pathologic findings in prospectively ascertained essential tremor subjects. *Neurology* 2008;70(16 Pt 2):1452–1455. [PubMed: 18413570]
26. Petito CK, Hart MN, Porro RS, Earle KM. Ultrastructural studies of olivopontocerebellar atrophy. *J Neuropathol Exp Neurol* 1973;32(4):503–522. [PubMed: 4357157]
27. Mann DM, Stamp JE, Yates PO, Bannister CM. The fine structure of the axonal torpedo in Purkinje cells of the human cerebellum. *Neurol Res* 1980;1(4):369–378. [PubMed: 6107881]
28. Louis ED, Yi H, Erickson-Davis C, Vonsattel JP, Faust PL. Structural study of Purkinje cell axonal torpedoes in essential tremor. *Neurosci Lett* 2009;450(3):287–291. [PubMed: 19047012]
29. Benito-Leon J, Louis ED, Bermejo-Pareja F. Risk of incident Parkinson's disease and Parkinsonism in essential tremor: A population-based study. *Neurology* 2008;70(Suppl 1):A191.
30. Bermejo-Pareja F, Louis ED, Benito-Leon J. Risk of incident dementia in essential tremor: A population-based study. *Mov Disord* 2007;22:1573–1580. [PubMed: 17516478]
31. Rajput A, Robinson CA, Rajput AH. Essential tremor course and disability: A clinicopathologic study of 20 cases. *Neurology* 2004;62(6):932–936. [PubMed: 15037695]

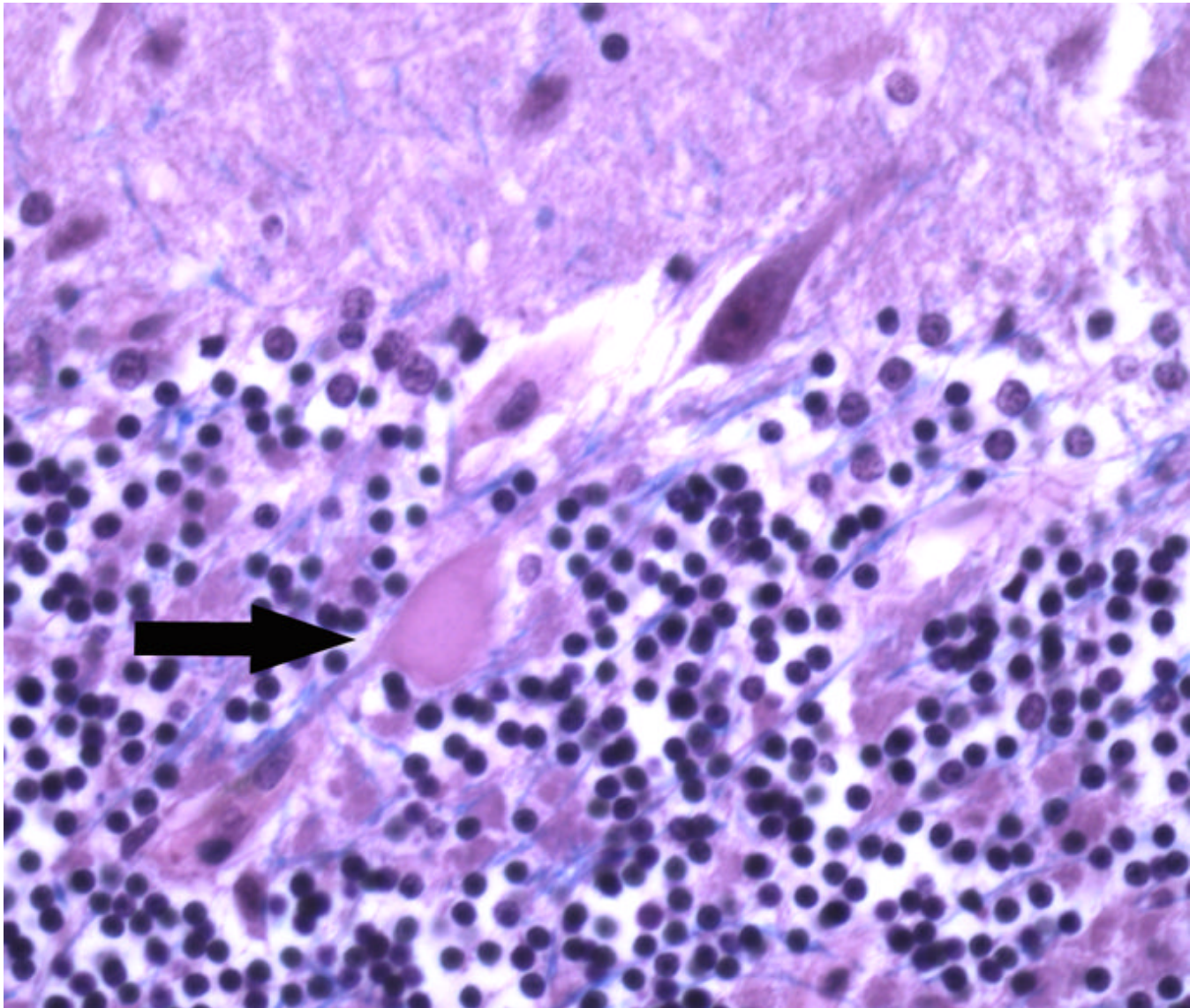


Figure 1. Number of torpedoes per section by diagnosis. Using a standard 20 × 25 mm LH&E-stained cerebellar section that included portions of the cerebellar cortex, white matter, and dentate nucleus, torpedoes in the entire section were counted. The Y axis shows the mean number of torpedoes per section ± one standard error.

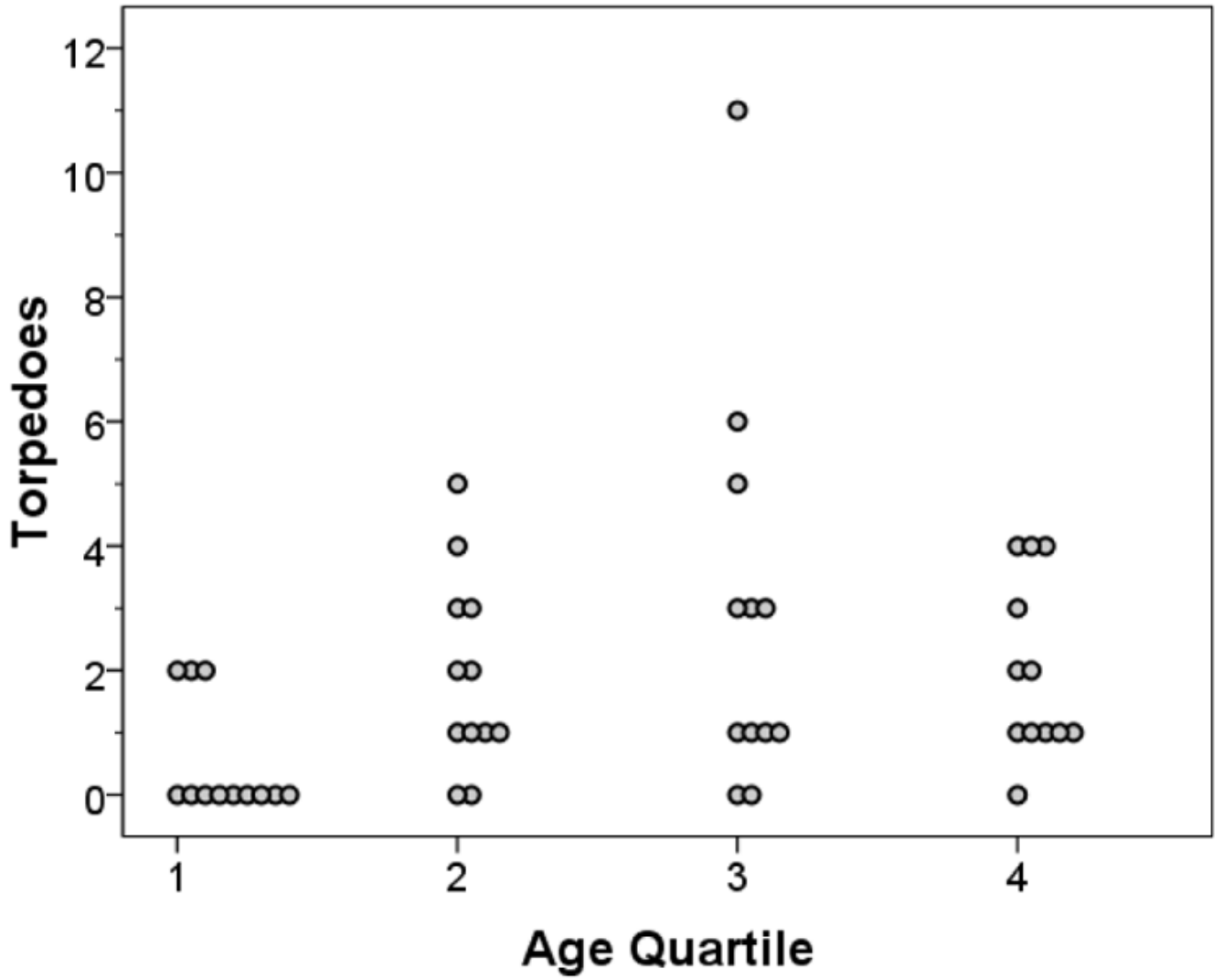


Figure 2.

Table 1

Clinical characteristics and pathological changes

| | Cerebellar ET (N = 34) | LBVET (N = 6) | PD or DLBD (N = 14) | AD (N = 21) | Controls (N = 25) |
|-------------------------------|------------------------|---------------|---------------------|-------------|-------------------|
| Age at death in years | 83.8 ± 7.7 | 89.3 ± 4.3* | 77.3 ± 6.0 | 83.4 ± 5.6 | 78.6 ± 10.1 |
| Female gender | 21 (61.8%) | 3 (50.0%) | 4 (28.6%) | 11 (52.4%) | 9 (36.0%) |
| PMI in hours ¹ | | | | | |
| Mean ± SD | 5.5 ± 3.2 | 6.9 ± 2.1 | 7.0 ± 5.6 | 6.3 ± 6.0 | 7.8 ± 7.3 |
| Median | 4.5 | 7.1 | 7.0 | 5.3 | 5.0 |
| Brain weight in grams | 1208 ± 130 | 1203 ± 150 | 1159 ± 353 | 1107 ± 114* | 1258 ± 123 |
| CERAD plaque score | | | | *** | |
| 0 | 14 (51.9%) | 3 (50.0%) | 4 (28.6%) | 0 (0.0%) | 18 (72.0%) |
| A | 9 (33.3%) | 1 (16.7%) | 3 (21.4%) | 0 (0.0%) | 6 (24.0%) |
| B | 1 (3.7%) | 1 (16.7%) | 3 (21.4%) | 0 (0.0%) | 0 (0.0%) |
| C | 3 (11.1%) | 1 (16.7%) | 4 (28.6%) | 21 (100.0%) | 1 (4.0%) |
| Braak AD stage | ** | ** | | ** | |
| 0 | 3 (11.1%) | 2 (33.3%) | 4 (30.8%) | 0 (0.0%) | 12 (48.0%) |
| I | 5 (18.5%) | 0 (0.0%) | 4 (30.8%) | 0 (0.0%) | 10 (40.0%) |
| II | 11 (40.7%) | 1 (16.7%) | 4 (30.8%) | 0 (0.0%) | 0 (0.0%) |
| III | 3 (11.1%) | 3 (50.0%) | 1 (7.7%) | 0 (0.0%) | 1 (4.0%) |
| IV | 5 (18.5%) | 0 (0.0%) | 0 (0.0%) | 0 (0.0%) | 1 (4.0%) |
| V | 0 (0.0%) | 0 (0.0%) | 0 (0.0%) | 6 (28.6%) | 1 (4.0%) |
| VI | 0 (0.0%) | 0 (0.0%) | 0 (0.0%) | 15 (71.5%) | 0 (0.0%) |
| Torpedoes (LH&E) ² | | | | | |
| Mean ± SD | 15.0 ± 12.2 | 3.7 ± 5.1 | 6.1 ± 6.3 | 7.3 ± 6.9 | 2.0 ± 1.6 |
| Median | 12 | 2 | 5 | 5 | 1 |
| P value ³ | <0.001 | 0.58 | 0.02 | 0.002 | Not applicable |

| | Cerebellar ET (N = 34) | LBVET (N = 6) | PD or DLBD (N = 14) | AD (N = 21) | Controls (N = 25) |
|----------------------|------------------------|---------------|---------------------|-------------|-------------------|
| P value ⁴ | Not applicable | 0.003 | 0.002 | 0.005 | <0.001 |

Unless otherwise specified, values are mean \pm SD or counts with percentages. CERAD plaque score was not available on 7 cerebellar ET cases.

Braak AD stage was not available on 1 PD case and 7 cerebellar ET cases.

* $p < 0.05$ (ANOVA and Tukey's post test in comparison with controls).

** $p < 0.05$ (Chi-square test in comparison with controls).

¹ PMI = the number of hours between death and placement of the brain in a cold room or upon ice.

² Using a standard 20×25 mm LH&E-stained cerebellar section that included portions of the cerebellar cortex, white matter, and dentate nucleus, torpedoes in the entire section were counted.

³ vs. controls using a Mann-Whitney test.

⁴ vs. cerebellar ET using a Mann-Whitney test.

⁵ vs. controls using a Chi-square test.

⁶ vs. cerebellar ET using a Chi-square test.