

Brief Report

Multichannel Electromyographic Mapping to Optimize OnabotulinumtoxinA Efficacy in Cervical Dystonia

Camilla Kilbane^{1,2}, Jill Ostrem^{1,2}, Nicholas Galifianakis^{1,2}, Jamie Grace¹, Leslie Markun¹ & Graham A. Glass^{1,2*}

¹ Department of Neurology, University of California, San Francisco, San Francisco, California, United States of America. ² Parkinson's Disease Research, Education, and Clinical Center, San Francisco Veterans Affairs Medical Center, San Francisco, United States of America

Abstract

Background: Cervical dystonia (CD) is characterized by sustained, involuntary contraction of head and neck muscles. Botulinum toxin injections are established as safe and effective, but unfortunately 15–25% of patients fail to respond. The aim of this study was to examine whether multichannel electromyographic mapping improved outcomes in a cohort of antibody-negative onabotulinumtoxinA non-responders by more precisely identifying which muscles were involved in the dystonia.

Methods: Patients with cervical dystonia who had “failed chemodenervation therapy” administered by an outside provider were enrolled in a single-blind, randomized, crossover design study. Patients received either a multichannel electromyographic mapping study prior to the first botulinum toxin injection, which was followed by use of only a single-lead injection 16 weeks later (injected by an alternate and blinded movement disorders specialist) or vice versa. The primary outcome measure was change in total Toronto Western Spasmodic Torticollis Rating Scale score 4 weeks after each injection compared with each pre-injection baseline score.

Results: Nine subjects completed this study. Mean percentage improvement in Total Toronto Western Spasmodic Torticollis Rating Scale was 23.5% using multichannel electromyography compared with 9% using the single-channel technique ($p=0.11$).

Discussion: This pilot study suggests that multichannel electromyographic mapping may result in improved efficacy in the treatment of antibody-negative onabotulinumtoxinA refractory CD.

Keywords: Cervical dystonia, botulinum toxin, torticollis, botulinum toxin non-responders, electromyography

Citation: Kilbane C, Ostrem C, Galifianakis N, et al. Multichannel electromyographic mapping to optimize onabotulinumtoxinA efficacy in cervical dystonia. *Tremor Other Hyperkinet Mov* 2012;2: <http://tremorjournal.org/article/view/91>

*To whom correspondence should be addressed. E-mail: graham.glass@ucsf.edu

Editor: Elan D. Louis, Columbia University, United States of America

Received: February 8, 2012 **Accepted:** April 30, 2012 **Published:** August 28, 2012

Copyright: © 2012 Kilbane et al. This is an open-access article distributed under the terms of the Creative Commons Attribution–Noncommercial–No Derivatives License, which permits the user to copy, distribute, and transmit the work provided that the original author(s) and source are credited; that no commercial use is made of the work; and that the work is not altered or transformed.

Funding: This study was funded by an Investigator Initiated unrestricted grant from Allergan, Inc.

Financial disclosures: Dr Ostrem is a consultant for Ipsen Inc, Merz Inc, Boston Scientific Inc. and is on an advisory board for Ipsen Inc., and Merz Inc. She has received honoraria from Medtronic Inc. and Allergan Inc and currently receives research grant funding from St. Jude Medical and MRI Interventions Inc. (formally called SurgiVision). She is also mentor for a fellowship grant from Medtronic Inc. Dr Glass has received honoraria from Allergan Inc for speaking engagements over 24 months ago. He has reviewed medical records for malpractice cases but has not testified to date. Dr Kilbane has received a travel stipend for conference attendance from Allergan Inc. and a fellowship grant from Medtronic Inc.

Conflict of Interest: The authors report no conflict of interest.

Introduction

Cervical dystonia (CD), also known as spasmodic torticollis, is a focal dystonia characterized by sustained, involuntary contractions of the muscles of the neck and shoulders resulting in abnormal and painful posturing of the head, neck, and shoulders.¹ Intermittent spasms and tremors can be superimposed upon longer muscle contractions. Pain is present in up to 60% of patients, and is sometimes the most disabling feature.² It is typically a life-long disease

that may wax and wane in severity and represents the most common form of focal dystonia seen in neurological practice, with a prevalence of 89 per 1 million people.³

A variety of oral medications have been used to treat CD, including benzodiazepines, anticholinergics and baclofen, but side effects usually limit their benefit.

Botulinum toxin injections are currently established as safe and effective in the treatment of CD⁴ and can provide relief for up to 85% of patients.⁵

Unfortunately, a significant minority of patients (between 15% and 25%) have a suboptimal response to chemodenervation therapy with botulinum toxin. Patients who develop symptoms refractory to treatment after multiple rounds of toxin injections may have developed neutralizing antibodies, although the incidence of such antibodies is approximately 0.5–1.2 % with the newer botulinum toxin A preparations.^{6,7} It is possible that in some patients the correct cervical muscles are not targeted, or that the dystonic muscle pattern changes over time. Some investigators feel that most patients with CD have one predominant abnormal head posture vector, thus indicating predictable patterns of dystonic muscle involvement.⁸ Others feel that CD is produced by a variety of vectors in multiple planes,⁹ which highlights the need for more sophisticated muscle targeting.

The primary reason cited in favor of electromyography (EMG)-assisted injections is the ability to identify abnormally contracting muscles that contribute to the dystonic posture of the head and neck. Although more than 26 muscle pairs control head and neck movements,¹⁰ only six pairs of muscles are routinely injected with botulinum toxin in the treatment of CD. Of these, three are easily palpable from the surface (sternocleidomastoid, trapezius, splenius capitis) whereas three are largely concealed by more superficial muscles (scalene complex, levator scapulae, cervical paraspinals). Most practices currently use single-lead electromyography at the time of injection to confirm accurate muscle selection. Unfortunately, this may represent an inadequate way of determining if a muscle is involved in the dystonia, as the pain and discomfort associated with the needle insertion often makes interpretation of the muscle activity difficult. Further, lack of symmetric evaluation of a muscle results in difficulty in differentiating compensatory muscle activity from dystonic activity. Clinical electrodiagnostic expertise also tends to be limited among many neurologists, thus often making EMG needle techniques as well as EMG interference pattern recognition suboptimal.

Electromyographic “mapping” involves symmetric insertion of multiple small EMG recording needles into all major muscles of the neck, and simultaneous recording of dystonic muscle activity, thus overcoming these shortfalls. Previous electromyographic “mapping” studies have shown that clinical examination alone is insufficient in determining which muscles contribute to the abnormal head movement. Based on clinical examination, experienced movement disorder neurologists correctly identified only 59% of the active and involved muscles, as well as falsely identified 25% of muscles found to be inactive via mapping as involved in dystonic movements.¹¹

The objective of the current study was to determine if patients with CD who have failed to respond adequately to standard treatment with onabotulinumtoxinA may have a better response after receiving a multichannel electromyographic mapping study of 12 cervical muscles prior to toxin injection for improved muscle targeting.

Methods

The study was approved by the University of California San Francisco Institutional Review Board and Committee on Human Research. Written informed consent was obtained from all subjects.

Patients without satisfactory response to onabotulinumtoxinA administration at an outside facility were enrolled. Patient enrollment commenced September 17, 2008, with the end of study procedures on October 28, 2010. Inclusion criteria included suboptimal response by patient history to two previous botulinum toxin injections at an outside facility, no chemodenervation for 16 weeks prior to enrollment, and at least moderate severity of CD with a baseline rating of 30 or more on the total Toronto Western Spasmodic Torticollis Scale (TWSTRS). The TWSTRS is a rating scale frequently used in clinical trials to measure the impact of cervical dystonia.

It includes a severity, disability, and a pain scale. Patients were selected from outside referrals, as we felt this more accurately reflected common injection techniques used in the community, rather than a tertiary dystonia treatment clinic. Patients with cervical muscle contractures, spinal deformities as well as post-traumatic CD were excluded. One patient was excluded due to lack of response to onabotulinumtoxinA on frontalis testing. Patient demographics were also collected. A baseline battery of rating scales including the TWSTRS, the Global Clinical Impression Scale (GCIS), and the Visual Analog Scale (VAS) for pain were obtained. Patients received either a multichannel electromyographic mapping study prior to the first botulinum toxin injection followed by use of only a single-lead injection 16 weeks later (injected by an alternate and blinded movement disorders specialist) or injection with the single-lead EMG first, followed by injection with the use of a multichannel EMG study. Four weeks after each injection, the TWSTRS, GCIS, and VAS were repeated. Multichannel EMG activity was rated on a scale of 0–4, and this information was used to help guide the choice of muscles. Medication regimens remained unchanged throughout the study to avoid confounding the clinical response to the toxin. The number of neurotoxin units injected was left to the discretion of each movement disorder neurologist and were recorded. The following muscles were targeted during the mapping study: bilateral sternocleidomastoids, splenius capitis, levator scapulae, cervical paraspinals (semispinalis), posterior scalenes, and trapezii. Adverse events were also collected.

The data were analyzed using the statistical package STATA (Stata Corp., College Station, Texas) The Wilcoxon Rank Sum test (non-parametric) was used to compare these two related samples to assess whether the population means differed significantly from each other. A p-value of 0.05 or lower was set as statistically significant.

The primary outcome was percentage change in total TWSTRS score 4 weeks after each injection compared with each pre-injection baseline score. Secondary outcomes included mean percentage change in the TWSTRS severity, disability, and pain scores. The amount of neurotoxin injected was also compared between injection techniques.

Results

Ten patients with CD were initially enrolled; however, one patient was excluded due to lack of response to the frontalis test. Nine subjects (five females) completed this single-blind, randomized, crossover design study. The mean age of disease onset was 52.3 years (range 28–65 years) and the mean disease duration was 9.4 years (range 1–23 years)

at the time of study entry. The mean baseline total TWSTRS was 47.4. There were no adverse events reported. All nine patients presented with predominantly rotational torticollis and/or laterocollis.

The mean change in total TWSTRS score was 13.44 points (range 1.5–28.25) or 23.5% (range 3.8–52.8%) using the multichannel EMG information compared with a mean of 5.1 points (range –9 to 24.25) or 9% (range –25.7% to 46.9%) when using only single-channel EMG ($p=0.11$) (Table 1). There was a trend for improved outcomes in the multichannel EMG group in all subscales, although more notable in the severity and disability subscales. The mean improvement in the severity subscale was 5.33 points (range 1–15) or 24.7 % (range 0–37.5%) in the multichannel EMG arm compared with 2.33 points (range –2 to 7 points) or 11.9% (range –15.4% to 20.8%) in the single-channel EMG arm ($p=0.06$). The disability subscore was improved by a mean of 2.77 points (range –1 to 7) or 16.1 % (range –7% to 36.8%) in the multichannel arm compared with 1.33 points (range –5 to 12) or 4.9% (range –35.7 to 18.8 %) in the single-channel arm ($p=0.04$). This result reached statistical significance. Interestingly there was less difference in outcome in pain subscales between the two injection techniques, with a mean percentage improvement of 19.7 % (range –40% to 52.8%) using multichannel EMG compared with 15.5% in the single-channel arm (range –12.5 to 35.6%) ($p=0.26$) (Table 1) (Figures 1 and 2).

The number of units of onabotulinumtoxinA injected was more dependent on injector than technique. The mean units of neurotoxin injected using the multichannel technique was 231 compared with 216 using the single-channel technique ($p=0.9$).

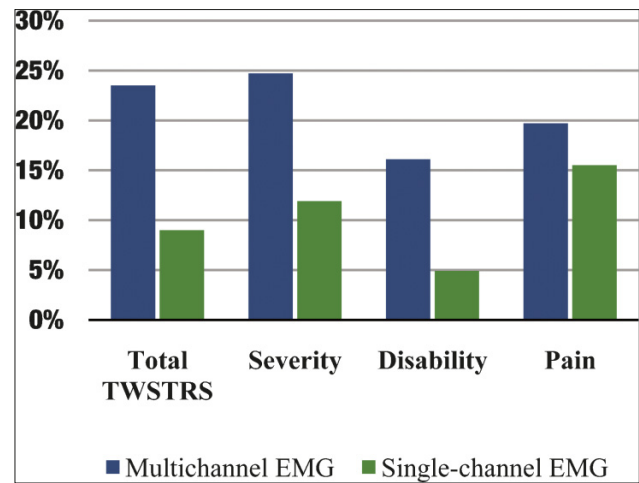


Figure 1. Mean Percentage Change in Total Toronto Western Spasmodic Torticollis Scale (TWSTRS) and Subscales in Patients Treated with Multichannel and Single-Channel Electromyographic Botulinum Toxin Injections. Multichannel electromyographic mapping was associated with improved outcome in all subscales and total TWSTRS scores, although it only reached statistical significance in the disability subscale.

Discussion

A previous study by Comella et al.¹² examined the effect of EMG guidance prior to botulinum toxin injection for treatment of cervical dystonia. Patients who underwent both a clinical and electromyographic examination prior to single-channel EMG botulinum toxin injection ($n=28$) had a significantly more robust response than those

Table 1. Mean and Median Point Change and Mean Percentage Improvement in Total TWSTRS and TWSTRS Subscales in Patients Treated with Both Multichannel and Single-Channel Electromyography

	Multichannel EMG: Mean Point Change ±SD (mean percentage change)	Multichannel EMG: Median Point Change (±IQR)	Single-channel EMG: Mean Point Change ±SD (mean percentage change)	Single-channel EMG: Median Point Change ±IQR	p-Value
Total TWSTRS	13.44 ± 9.95 (23.5%)	8.5 (± 16.25)	5.1 ± 9.73 (9%)	3.5 (± 12)	$p=0.11$
TWSTRS severity	5.33 ± 4.79 (24.7%)	4 (± 5)	2.33 (± 2.87) (11.9%)	1 (± 4)	$p=0.06$
TWSTRS disability	2.77 ± 2.38 (16.1%)	3 (± 2)	1.33 (± 4.82) (4.9%)	1 (± 4)	$p=0.04$
TWSTRS pain	2.88 ± 3.67 (19.7%)	2.25 (± 5.25)	1.41 (± 3.48) (15.5%)	1.5 (± 1.75)	$p=0.26$
Mean number of neurotoxin units injected	231		216		$p=0.90$

Abbreviations: EMG, electromyography; IQR, interquartile range; SD, standard deviation; TWSTRS, Toronto Western Spasmodic Torticollis Scale.

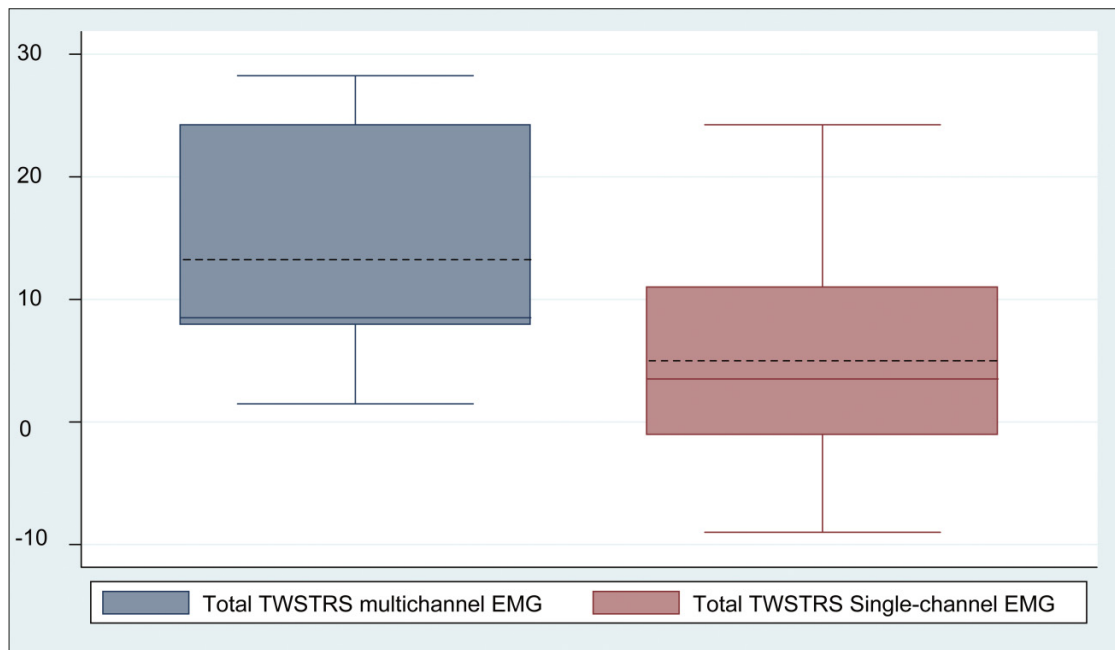


Figure 2. Mean and Median Change in Total Toronto Western Spasmodic Torticollis Scale, using Multichannel and Single-Channel Electromyographic Technique (mean value, dotted line; median value, solid line).

whose muscles were selected for injection based solely on clinical examination and injected without EMG assistance ($n=24$). The percentage of patients achieving benefit was similar in both groups; however, the magnitude of improvement and the number of patients able to achieve marked improvement was significantly higher in the EMG-assisted group.

In particular, patients with retrocollis, head tilt, and shoulder elevation demonstrated additional benefit with EMG-assisted botulinum toxin injection. The authors postulated that EMG assistance was more effective because the technique increases the ability to effectively identify and treat the deep cervical muscles.¹² Van Gerpen et al.¹¹ examined the accuracy of experienced movement disorder neurologists in predicting dystonic involvement of individual muscles compared with an EMG mapping study in 20 untreated cases of CD. The sensitivity of the clinical examination was 59% and the specificity 75%. Almost half of the patients (45%) studied had a single dystonic head vector, thus making muscle targeting theoretically easier. In the five patients with pure rotational torticollis, all had dystonia of the expected contralateral sternocleidomastoid and four of the ipsilateral splenius capitis. Interestingly three patients also had dystonia of the ipsilateral semispinalis, levator scapulae, or the contralateral posterior scalene, and two had involvement of the contralateral splenius capitis, semispinalis or ipsilateral posterior scalene, or trapezius.¹¹ This highlights the fact that clinical examination alone may not be sufficient in correctly identifying muscles involved in even single-vector cervical dystonia.

In our cohort of previously onabotulinumtoxinA non-responsive patients, the mean percentage improvement in total TWSTRS score

when electromyographic mapping was used was 23.5% versus 9% when only a single-lead EMG technique was performed. A larger improvement was also seen across all TWSTRS subscores in the multichannel EMG group than in single-channel mapping. Although a small pilot study is in no way conclusive, the results are consistent with previous data that highlight the role of more extensive mapping procedures to properly identify the appropriate muscles to target, especially in challenging cases. As this type of study certainly is time consuming, adds costs, and also causes some additional patient discomfort, we suggest using this technique for refractory cases where the frontalis test shows continued sensitivity to neurotoxins.

In summary, this pilot study does suggest that multichannel electromyographic mapping may result in improved efficacy in the treatment of antibody negative onabotulinumtoxinA refractory CD patients.

References

1. Jankovic J, Tolosa E. Parkinson's disease and movement disorders. Baltimore, MD: Urban & Schwarzenberg, 1988.
2. Chan J, Brin MF, Fahn S. Idiopathic cervical dystonia: clinical characteristics. *Mov Disord* 1991;6:119–126, <http://dx.doi.org/10.1002/mds.870060206>.
3. Nutt JG, Muentner MD, Aronson A, Kurland LT, Melton LJ, 3rd. Epidemiology of focal and generalized dystonia in Rochester, Minnesota. *Mov Disord* 1988;3:188–194, <http://dx.doi.org/10.1002/mds.870030302>.
4. Simpson DM, Blitzer A, Brashear A, et al. Therapeutics and Technology Assessment Subcommittee of the American Academy of Neurology. *Neurology* 2008;70(19):1699–706, doi: <http://dx.doi.org/10.1212/01.wnl.0000311389.26145.95>

5. Comella CL, Thompson PD. Treatment of cervical dystonia with botulinum toxins. *Eur J Neurol* 2006;13(Suppl 1):16–20, <http://dx.doi.org/10.1111/j.1468-1331.2006.01440.x>.
6. Yablon SA, Brashear A, Gordon MF, et al. Formation of neutralizing antibodies in patients receiving botulinum toxin type A for treatment of poststroke spasticity: a pooled-data analysis of three clinical trials. *Clin Ther* 2007;29:683–690, <http://dx.doi.org/10.1016/j.clinthera.2007.04.015>.
7. Brin MF, Comella CL, Jankovic J, Lai F, Naumann M. Long-term treatment with botulinum toxin type A in cervical dystonia has low immunogenicity by mouse protection assay. *Mov Disord* 2008;23:1353–1360, <http://dx.doi.org/10.1002/mds.22157>.
8. Deuschl G, Heinen F, Kleedorfer B, Wagner M, Lucking CH, Poewe W. Clinical and polymyographic investigation of spasmodic torticollis. *J Neurol* 1992;239:9–15, <http://dx.doi.org/10.1007/BF00839204>.
9. Dauer WT, Burke RE, Greene P, Fahn S. Current concepts on the clinical features, aetiology and management of idiopathic cervical dystonia. *Brain* 1998; 121:547–560, <http://dx.doi.org/10.1093/brain/121.4.547>.
10. Berkovitz BKB, Moxham BJ, Brown MW. A textbook of head and neck anatomy. London: Wolfe Medical Publications, 1988.
11. Van Gerpen JA, Matsumoto JY, Ahlskog JE, Maraganore DM, McManis PG. Utility of an EMG mapping study in treating cervical dystonia. *Muscle Nerve* 2000;23:1752–1756, [http://dx.doi.org/10.1002/1097-4598\(200011\)23:11<1752::AID-MUS12>3.0.CO;2-U](http://dx.doi.org/10.1002/1097-4598(200011)23:11<1752::AID-MUS12>3.0.CO;2-U).
12. Comella CL, Buchman AS, Tanner CM, Brown-Toms NC, Goetz CG. Botulinum toxin injection for spasmodic torticollis: increased magnitude of benefit with electromyographic assistance. *Neurology* 1992;42:878–882, <http://dx.doi.org/10.1212/WNL.42.4.878>.